

## Ovarian adenosarcoma simulating a simple cyst in a young patient

Leonardo Gomes da Fonseca<sup>a</sup>, Aloísio Felipe-Silva<sup>b</sup>,  
Samanta Cabral Severino da Silva<sup>a</sup>, Paulo Francisco Ramos Margarido<sup>c</sup>,  
Elias Abdo Filho<sup>a</sup>, Paulo Marcelo Gehm Hoff<sup>a</sup>

Fonseca LG, Felipe-Silva A, Silva SCS, Margarido PFR, Abdo Filho E, Hoff PMG. Ovarian adenosarcoma simulating a simple cyst in a young patient. *Autopsy Case Rep* [Internet]. 2014;4(2):55-60. <http://dx.doi.org/10.4322/acr.2014.011>

### ABSTRACT

Müllerian adenosarcoma is a rare, mixed tumor that can occur throughout the female genital tract, but is most commonly found in the uterus. Ovarian adenosarcoma is rarer and has a poorer prognosis than uterine adenosarcoma. Data on the clinicopathological features of ovarian adenosarcoma are limited, and, due to its rarity, the management is controversial. The authors report a case of a 25-year-old patient who presented with recurrent abdominal pain. Sonography and laparotomy showed an ovarian cyst, and pathologic examination confirmed the diagnosis of cystic low-grade adenosarcoma. The patient remains free of recurrence 6 months after diagnosis. The authors call attention to the differential diagnosis of ovarian masses, especially in young patients, and to the lack of evidence on the management of this neoplasm in the literature.

### Keywords

Mixed Tumor, Mullerian; Ovarian Neoplasms; Neoplasm Staging; Therapeutics.

### CASE REPORT

A 25-year-old woman sought the gynecology service complaining of right lower abdominal pain for the past 2 months. She denied fever or other local inflammatory signs. She had no past history of comorbidities. Her gynecologic history included nulliparity, menarche at 13 years of age, and regular menstrual cycles at 28-day intervals. There was no reported history of cancer in her family.

The physical examination was normal except for a mobile mass in the right lower abdomen.

Pelvic ultrasonography revealed a right paraovarian cyst with a smooth outline and areas of a vaguely

nodular thickening of the wall. The content was hypoechoic and a solid component was not detected. Serum chorionic gonadotropin was < 3 IU/L (reference value: < 3 IU/L) and complementary laboratory workup was normal. Considering the hypothesis of paraovarian cyst, the initial management was observation.

After 2 months of follow-up, the patient complained of worsening abdominal pain, so a laparotomy was performed. An 8-cm simple cyst with a smooth surface was seen in the right ovary. A yellowish liquid was drained from the cyst before its dissection

<sup>a</sup> Department of Clinical Oncology - Instituto do Câncer do Estado de São Paulo – São Paulo/SP - Brazil.

<sup>b</sup> Anatomic Pathology Service - Hospital Universitário - Universidade de São Paulo, São Paulo/SP - Brazil.

<sup>c</sup> Department of Gynecology - Hospital Universitário - Universidade de São Paulo, São Paulo/SP - Brazil.

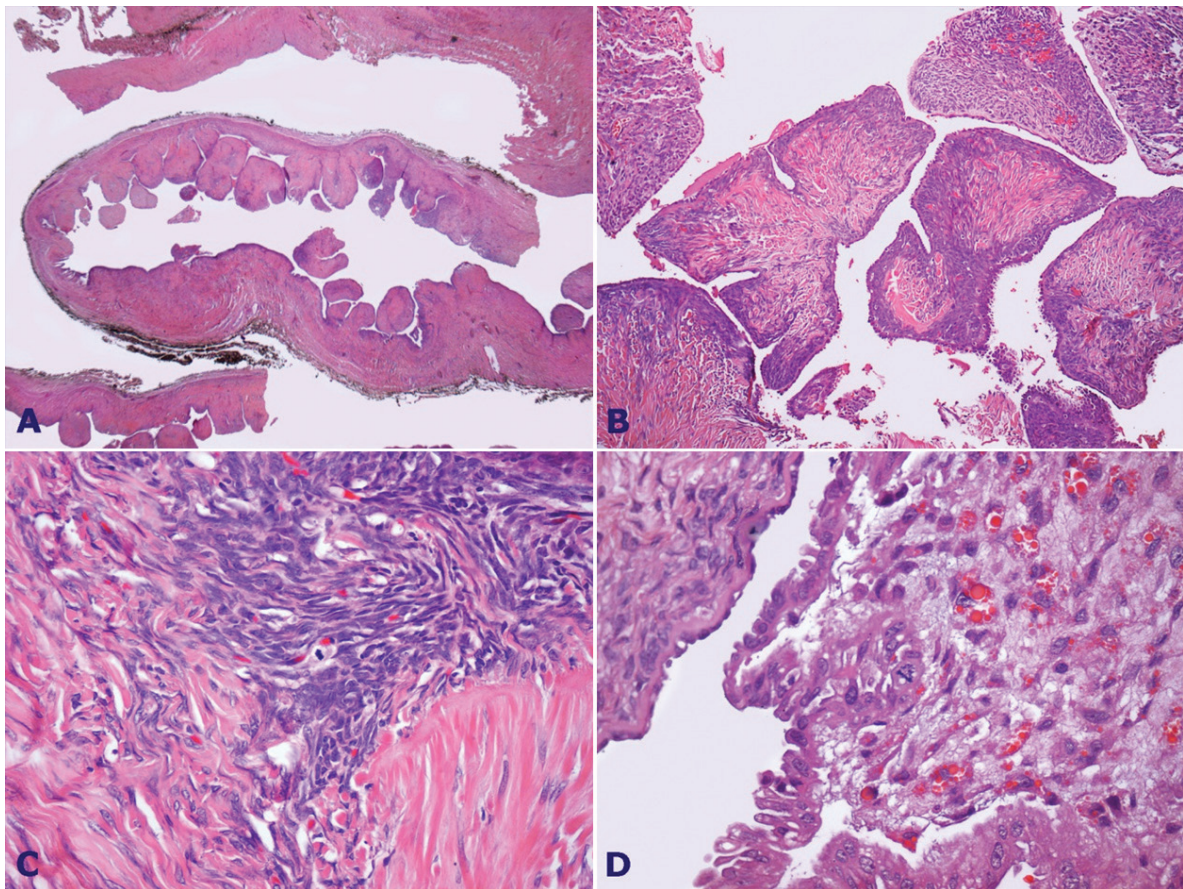


and exeresis (simple cystectomy). On gross examination the uterus and fallopian tubes were normal.

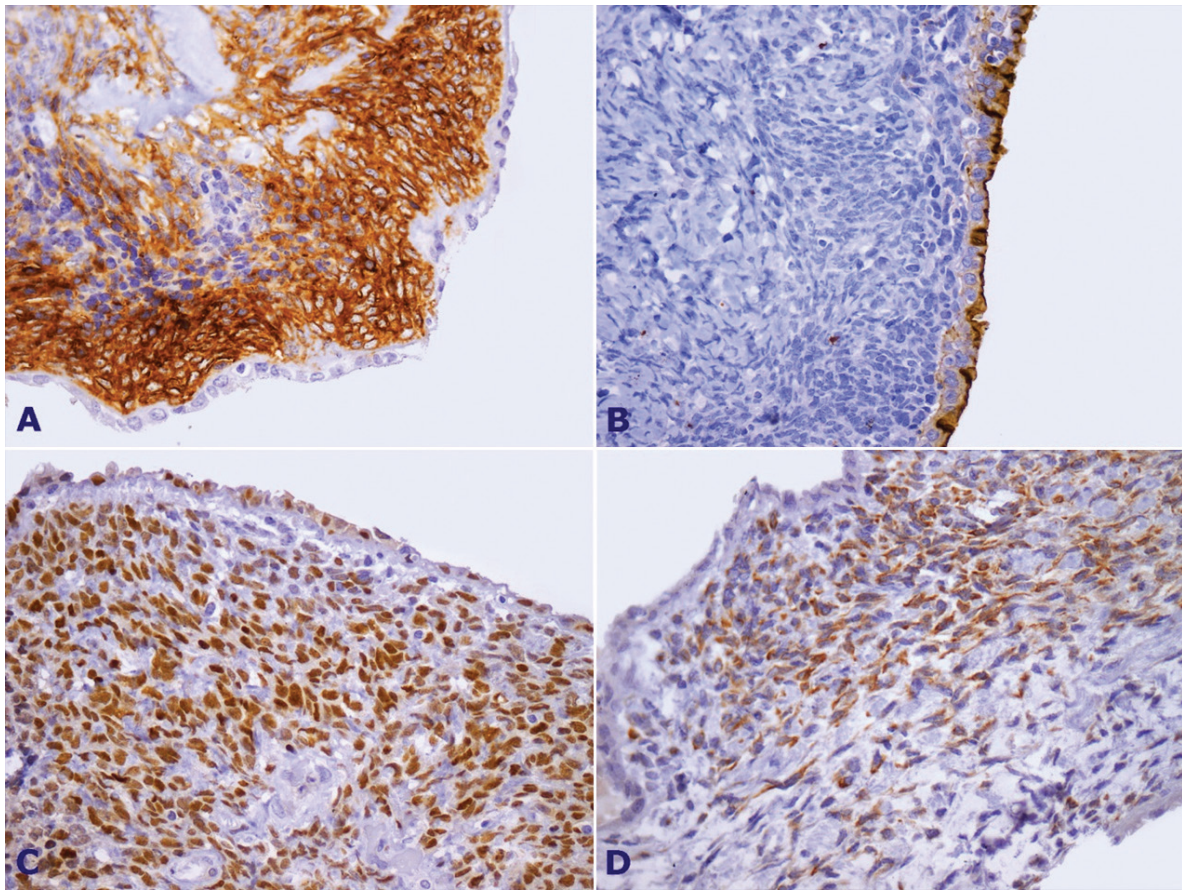
Pathological examination showed a thin-walled (0.2–0.5 cm) cystic tumor with a smooth external surface. The internal surface showed multiple small (0.2–0.3 cm) whitish, firm, and sometimes coalescent vegetation. The microscopic examination showed a mixture of slight atypical serous or endometrioid epithelia with an atypical stroma. The mesenchymal component consisted of endometrial stromal sarcoma-like tissue, with slight-to-moderate atypia, foci of fibrous appearance, and striking subepithelial cuffs of cellular stroma and intracystic protrusions (Figure 1). Some hyaline globules were present in the stromal component. Up to two mitotic figures in 10 high-power fields were counted in the stromal and epithelial components. There was no vascular or perineural invasion and the ovarian capsule was intact. Sarcomatous overgrowth was not detected.

The immunohistochemical panel was compatible with a diagnosis of low-grade ovarian adenosarcoma. Tumor stromal cells were positively stained with vimentin, smooth-muscle actin, desmin, CA125, CD10, progesterone receptor, and focally with estrogen receptor. Epithelial cells were stained with CA125, vimentin, progesterone, and estrogen receptors. Proliferation index as accessed by Ki-67 was 5% (Figure 2). MyoD1 and myogenin (rhabdomyoblastic markers) were negative.

The patient was referred to a cancer center where a right oophorectomy and surgical staging were performed. The surgery included right-salpingo-oophorectomy, omentectomy, and peritoneal washing. Pathological examination showed foci of endometriosis in the right ovary and there was no evidence of malignancy. The pathological staging was pT1aN0M0 (FIGO IA).<sup>1</sup> No adjuvant treatment was required and the patient remains free of recurrence 6 months after first diagnosis.



**Figure 1.** **A** – Photomicrography showing papillary projections into the cyst (H&E, 12.5x); **B** – Papillary projections with dense sub-epithelial stromal cuffs (H&E; 100x); **C** – Mitosis in endometrial stromal sarcoma-like tissue (H&E, 400x); **D** – Mitosis in epithelial cell and stromal hyaline globules (H&E; 400x).



**Figure 2.** Photomicrography of immunohistochemistry. **A** – CD10 staining in stromal cuff (400x); **B** – CA125 staining in epithelial cells (400x); **C** – Progesterone receptor staining in epithelial and stromal elements (400x); **D** – Desmin staining in stromal cells (400x).

## DISCUSSION

The first description of Müllerian adenosarcoma was in 1974, by Clement and Scully.<sup>2</sup> These tumors are rare and are characterized by a mixture of benign glandular epithelium and a low-grade malignant sarcomatous stroma resembling that of endometrial stromal sarcoma.<sup>3</sup>

Adenosarcoma most commonly arises in the uterine endometrium, but extrauterine sites such as ovary, pelvic sidewall, cervix, and myometrium were reported previously.<sup>4-7</sup> The main clinical manifestations are dependent on the location and include vaginal bleeding, abdominal pain, abdominal distension, ascites, and intestinal disorders.<sup>8</sup> These manifestations are also found in many other pelvic diseases and physiological states, such as the menstrual period. Not only clinically, but also pathologically, ovarian adenosarcoma is difficult to diagnose.

Adenosarcomas are composed of two intermixed neoplastic tissues of different malignant potential:

a benign epithelial component, with glands lined by benign proliferative endometrium-like cells and a sarcomatous component, with spindle-shaped or round cells that show cytologically malignant features.<sup>9</sup> Differential diagnosis include adenofibroma, which is composed of benign epithelial and mesenchymal elements; and carcinosarcoma, which is composed of distinctive and separate, but admixed, carcinomatous and sarcomatous elements. Both are considered mixed Müllerian tumors.<sup>10</sup>

The origin of adenosarcoma is not clear. While some authors advocate a biphasic origin, others believe that the tumor originates from a multipotential stem cell.<sup>11</sup> Endometrioma has been suggested to be the histologic precursor.<sup>12</sup> Extrauterine adenosarcoma has been reported in sites where endometriosis is common, including the pelvic sidewall, peritoneum, colon, and ovary.<sup>8,13</sup> The development of adenosarcoma on a background of endometriosis in the ovary has also been reported.<sup>14-16</sup> Besides, previous reports called attention to the fact that adenosarcoma most commonly arises

in the topic endometrium and rarely in intramural endometrium (adenomyosis).<sup>6,11</sup> In the present case, endometriosis could be the precursor lesion as it was found after ovary removal.

Gross specimens from adenosarcomas are most commonly solid, but around 10% are predominantly cystic, similar to the present case.<sup>8,13</sup>

Ovarian adenosarcoma is generally more aggressive than uterine adenosarcoma and is associated with poorer prognosis and more advanced stage at presentation.<sup>8</sup> These tumors frequently tend to recur locally, and distant metastases are rare.<sup>2,8</sup> The reason for local recurrences could be the fact that ovarian adenosarcoma is susceptible to rupture and adherence to adjacent structures.<sup>8</sup>

Gollard et al. (1995)<sup>6</sup> revised 15 cases of ovary adenosarcoma. The average patient age was 48 years; there were six local recurrences and only one distant recurrence. Eichorn et al. (2002)<sup>8</sup> reported a series with 40 patients diagnosed with ovarian adenosarcoma in which the mean age was 54 years and the ovarian mass was unilateral in 97% of the patients. Also, median time to recurrence was 2.6 years and four women developed distant metastasis. The 5-, 10- and 15-year overall survival rates were 64%, 46%, and 30%, respectively, and death from tumor occurred in 37.5%.<sup>8</sup>

The prognosis of early stage malignant ovarian cancers with capsule rupture is still controversial. In a recent meta-analysis involving 2382 cases of early-stage epithelial ovarian cancer, the intraoperative rupture of the capsule did not present a worse prognosis, compared with those whose capsules remained intact (Hazard ratio [HR]: 1.49; 95% confidence interval [CI]: 0.45–4.95). Nevertheless, the prognosis of the preoperative rupture is worse compared with the intraoperative rupture (HR: 2.63; 95% CI: 1.11–6.20).<sup>22</sup> On the other hand, a retrospective cohort study involving 161 cases of FIGO stage I ovarian epithelial cancers (submitted to the same staging procedure) showed a worse prognosis in those cases where the rupture of the capsule occurred, compared with those whose capsule remained intact (HR: 3.6; 95% CI: 1.5–8.9; [p = 0.004]).<sup>23</sup>

The prognosis of ovarian adenosarcomas whose capsules were ruptured is unknown due to the lack of data in the literature. The cyst puncture is a controlled capsule rupture, with little or no drainage of the

cyst content into the abdominal cavity. In the case reported herein, we dare consider that the disease remained localized in the removed ovary, despite the puncture, considering the low malignant potential of this neoplasia and the restaging represented by the research of free neoplastic cells in the peritoneal lavage.

The recommended treatment is surgical resection (hysterectomy and bilateral salpingo-oophorectomy). An attempt to establish appropriate surgical and pathologic staging is crucial for management.<sup>17</sup> Whether adjuvant chemotherapy or radiotherapy may play a role in avoiding disease recurrence is not defined in the literature. radiotherapy may play a role in avoiding disease recurrence is not defined in the literature. Data on the behavior of low-grade tumors are scarce regarding young patients who wish to have children, although age under 53 years, a tumoral capsule rupture, high-grade morphology, and a predominance of tumoral sarcomatous component are considered to be worse prognosis risk factors. This is why radical surgical treatment should be individualized.<sup>24</sup>

Tumors originating from the uterus showed median time to recurrence of 5 years, and the local and distant recurrences are commonly composed of higher-grade sarcoma than that of the mesenchymal component of the original neoplasm. In rare cases, the recurrence is biphasic.<sup>18</sup> For these reasons, the systemic treatment of the recurrence or metastatic disease is commonly made with chemotherapy regimens directed to uterine and soft tissue sarcomas or carcinosarcomas, such as ifosfamide, cisplatin, doxorubicin, and dacarbazine.<sup>8,19-21</sup> The small number of reports do not allow a conclusion about the efficacy of these drugs and how they can affect clinical outcomes for metastatic disease.

## CONCLUSION

Adenosarcoma arising in the ovary is rare and carries a poorer prognosis than its uterine counterpart, with higher rates of recurrence. The present report exemplifies a case in which the patient was younger than the median age reported in case series of ovarian adenosarcoma and an uncommon cystic presentation. The low clinical initial suspicion made the diagnosis

surprising. Adenosarcoma should always be considered as a differential diagnosis in patients with solid or cystic pelvic masses, particularly in those with a history of endometriosis. The treatment consists of surgical resection and the role of chemotherapy or radiation is not clear. Clinical trials for ovarian adenosarcoma would be beneficial but multicentric studies may be necessary due to the rarity of this disease.

## REFERENCES

- Morgan RJ Jr, Alvarez RD, Armstrong DK, et al. Ovarian cancer, version 2.2013. *J Natl Compr Canc Netw*. 2013;11(10):1199-209. PMID:24142821.
- Clement PB, Scully RE. Müllerian adenosarcoma of the uterus. A clinicopathologic analysis of ten cases of a distinctive type of müllerian mixed tumor. *Cancer*. 1974;34(4):1138-49. [http://dx.doi.org/10.1002/1097-0142\(197410\)34:4<1138::AID-CNCR2820340425>3.0.CO;2-9](http://dx.doi.org/10.1002/1097-0142(197410)34:4<1138::AID-CNCR2820340425>3.0.CO;2-9). PMID:4371193
- Ostör AG, Fortune DW. Benign and low grade variants of mixed Müllerian tumour of the uterus. *Histopathology*. 1980;4(4):369-82. <http://dx.doi.org/10.1111/j.1365-2559.1980.tb02932.x>. PMID:6253378
- Clement PB, Scully RE. Extrauterine mesodermal (müllerian) adenosarcoma: a clinicopathologic analysis of five cases. *Am J Clin Pathol*. 1978;69(3):276-83. PMID:205129.
- Bard ES, Bard DS, Vargas-Cortes F. Extrauterine Müllerian adenosarcoma; a clinicopathologic report of a case with distant metastases and review of the literature. *Gynecol Oncol*. 1978;6(3):261-74. [http://dx.doi.org/10.1016/0090-8258\(78\)90031-8](http://dx.doi.org/10.1016/0090-8258(78)90031-8). PMID:208932
- Gollard R, Kosty M, Bordin G, Wax A, Lacey C. Two unusual presentations of müllerian adenosarcoma: case reports, literature review, and treatment considerations. *Gynecol Oncol*. 1995;59(3):412-22. <http://dx.doi.org/10.1006/gyno.1995.9950>. PMID:8522267
- Fayemi AO, Ali M, Braun EV. Müllerian adenosarcoma of the uterine cervix. *Am J Obstet Gynecol*. 1978;130(6):734-5. PMID:205133.
- Eichhorn JH, Young RH, Clement PB, Scully RE. Mesodermal (müllerian) adenosarcoma of the ovary: a clinicopathologic analysis of 40 cases and a review of the literature. *Am J Surg Pathol*. 2002;26(10):1243-58. <http://dx.doi.org/10.1097/00000478-200210000-00001>. PMID:12360039
- Fox H, Harilal KR, Youell A. Müllerian adenosarcoma of the uterine body: a report of nine cases. *Histopathology*. 1979;3(3):167-80. <http://dx.doi.org/10.1111/j.1365-2559.1979.tb02994.x>. PMID:468120
- D'Angelo E, Prat J. Pathology of mixed Müllerian tumours. *Best Pract Res Clin Obstet Gynaecol*. 2011;25(6):705-18. <http://dx.doi.org/10.1016/j.bpobgyn.2011.05.010>. PMID:21742560
- Oda Y, Nakanishi I, Tateiwa T. Intramural müllerian adenosarcoma of the uterus with adenomyosis. *Arch Pathol Lab Med*. 1984;108(10):798-801. PMID:6089698.
- Mahoney AD, Waisman J, Zeldis LJ. Adenomyoma: a precursor of extrauterine Müllerian adenosarcoma? *Arch Pathol Lab Med*. 1977;101(11):579-84. PMID:199134.
- Mckay DC, Ellis JH, Marn CS. CT of mullerian adenosarcoma arising in endometriosis. *Clin Imaging*. 1993;17(3):204-6. [http://dx.doi.org/10.1016/0899-7071\(93\)90111-Y](http://dx.doi.org/10.1016/0899-7071(93)90111-Y). PMID:8395963
- Inoue M, Fukuda H, Tanizawa O. Adenosarcomas originating from sites other than uterine endometrium. *Int J Gynaecol Obstet*. 1995;48(3):299-306. [http://dx.doi.org/10.1016/0020-7292\(94\)02267-3](http://dx.doi.org/10.1016/0020-7292(94)02267-3). PMID:7781874
- Stern RC, Dash R, Bentley RC, Snyder MJ, Haney AF, Robboy SJ. Malignancy in endometriosis: frequency and comparison of ovarian and extraovarian types. *Int J Gynecol Pathol*. 2001;20(2):133-9. <http://dx.doi.org/10.1097/00004347-200104000-00004>. PMID:11293158
- Al-Abbadi MA, Spanta R. Pathologic quiz case. A 34-year-old woman with abdominal pain and a large right multicystic ovarian mass. Müllerian adenosarcoma arising in an endometriotic cyst. *Arch Pathol Lab Med*. 2004;128(9):1057-8. PMID:15335245.
- Verschraegen CF, Vasuratna A, Edwards C, et al. Clinicopathologic analysis of müllerian adenosarcoma: the M.D. Anderson Cancer Center experience. *Oncol Rep*. 1998;5(4):939-44. PMID:9625851.
- McCluggage WG. Müllerian adenosarcoma of the female genital tract. *Adv Anat Pathol*. 2010;17(2):122-9. <http://dx.doi.org/10.1097/PAP.0b013e3181cfe732>. PMID:20179434
- Tate Thigpen J, Blessing JA, DeGeest K, Look KY, Homesley HD, and the Gynecologic Oncology Group. Cisplatin as initial chemotherapy in ovarian carcinosarcomas: a Gynecologic Oncology Group study. *Gynecol Oncol*. 2004;93(2):336-339. <http://dx.doi.org/10.1016/j.ygyno.2004.01.007>. PMID:15099942
- Baker TR, Piver MS, Lele SB, Tsukada Y. Stage I uterine adenosarcoma: a report of six cases. *J Surg Oncol*. 1988;37(2):128-32. <http://dx.doi.org/10.1002/jso.2930370213>. PMID:2830437
- Le T, Krepart GV, Lotocki RJ, Heywood MS. Malignant mixed mesodermal ovarian tumor treatment and

- prognosis: a 20-year experience. *Gynecol Oncol.* 1997;65(2):237-40. <http://dx.doi.org/10.1006/gyno.1997.4625>. PMID:9159331
22. Kim HS, Ahn JH, Chung HH, et al. Impact of intraoperative rupture of the ovarian capsule on prognosis in patients with early-stage epithelial ovarian cancer: a meta-analysis. *Eur J Surg Oncol.* 2013;39(3):279-89. <http://dx.doi.org/10.1016/j.ejso.2012.12.003>
- 23- Bakkum-Gamez JN, Richardson DL, Seamon LG, et al. Influence of intraoperative capsule rupture on outcomes in stage i epithelial ovarian cancer. *Obstet Gynecol.* 2009;113(1):11-7. <http://dx.doi.org/10.1097/AOG.0b013e3181917a0c>
- 24- McCluggage WG. Mullerian adenosarcoma of the female genital tract. *Adv Anat Pathol.* 2010;17(2):122-9. <http://dx.doi.org/10.1097/PAP.0b013e3181cfe732>

**Conflict of interest:** None

**Submitted on:** April 29, 2014

**Accepted on:** June 15, 2014

### Correspondence

Instituto do Câncer do Estado de São Paulo – ICESP  
Av. Dr. Arnaldo 251 – São Paulo/SP – Brazil  
Cep 01246-000

**Phone** +55 (11) 3893-2686

**E-mail** leogfonseca@hotmail.com