

Cat-scratch disease presenting as multiple hepatic lesions: case report and literature review

Mariana Andrade Baptista^a, Denise Swei Lo^b, Noely Hein^b, Maki Hirose^b,
Cristina Ryoka Miyao Yoshioka^b, Selma Lopes Betta Ragazzi^b,
Alfredo Elias Gilio^{a,b}, Angela Esposito Ferronato^b

Baptista MA, Lo DS, Hein N, et al. Cat-scratch disease presenting as multiple hepatic lesions: case report and literature review. *Autopsy Case Rep* [Internet]. 2014;4(2):43-8. <http://dx.doi.org/10.4322/acr.2014.016>

ABSTRACT

Although infectious diseases are the most prevalent cause of fevers of unknown origin (FUO), this diagnosis remains challenging in some pediatric patients. Imaging exams, such as computed tomography (CT) are frequently required during the diagnostic processes. The presence of multiple hypoattenuating scattered images throughout the liver associated with the history of cohabitation with cats should raise the suspicion of the diagnosis of cat-scratch disease (CSD), although the main etiologic agent of liver abscesses in childhood is *Staphylococcus aureus*. Differential diagnosis by clinical and epidemiological data with *Bartonella henselae* is often advisable. The authors report the case of a boy aged 2 years and 9 months with 16-day history of daily fever accompanied by intermittent abdominal pain. Physical examination was unremarkable. Abdominal ultrasound performed in the initial work up was unrevealing, but an abdominal CT that was performed afterwards disclosed multiple hypoattenuating hepatic images compatible with the diagnosis of micro abscesses. Initial antibiotic regimen included cefotaxime, metronidazole, and oxacillin. Due to the epidemiology of close contact with kittens, diagnosis of CSD was considered and confirmed by serologic tests. Therefore, the initial antibiotics were replaced by clarithromycin orally for 14 days followed by fever defervescence and clinical improvement. The authors call attention to this uncommon diagnosis in a child presenting with FUO and multiple hepatic images suggestive of micro abscesses.

Keywords

Cat-Scratch Disease; Fever of Unknown Origin; Liver Abscess.

INTRODUCTION

Fever of unknown origin (FUO) is defined, according to Petersdorf and Beeson,¹ and Lambertucci,² as a daily axillary temperature exceeding 38°C for more than 14 days without diagnostic signs and symptoms. This entity is responsible for approximately 8.4% of all hospitalizations among the adult population.^{2,3,4} In pediatrics, FUO is associated with infectious diseases,

connective tissue disorders, and malignancy. In 1998, Jacobs and Schutze⁵ studied 146 children with FUO, demonstrating that Epstein-Barr virus (EBV) infection was the leading cause of fever (15% [22/146]), followed by osteomyelitis (9% [14/146]). Cat-scratch disease (CSD) was the third most frequent etiology

^a Department of Pediatrics – Faculdade de Medicina – Universidade de São Paulo, São Paulo/SP – Brazil.

^b Department of Pediatrics – Hospital Universitário – Universidade de São Paulo, São Paulo/SP – Brazil.



(4.8% [7/146]). In this series, 76% of patients with confirmed diagnosis had an infectious disease.⁵

Hepatic abscess represents a relevant hypothesis to be considered in children with FUO and abdominal pain.⁶ We report the case of a child who presented FUO and unspecific abdominal pain, firstly diagnosed as bacterial (staphylococcal/mixed flora) hepatic micro abscesses based on an imaging examination. During hospitalization, epidemiological evidence came to the fore favoring the diagnosis of CSD, which was further confirmed by serology. Treatment was then directed towards *Bartonella henselae*, with a favorable outcome.

CASE REPORT

A previously healthy young boy, aged 2 years and 9 months, sought the pediatric emergency department of a general hospital, complaining of fever during the last 16 days, with no other complaint. During this period, the family had attended other medical facilities without a definite diagnosis. Physical examination disclosed a well-looking patient, afebrile, hydrated, acyanotic, and anicteric. Pulses were wide and symmetric and of peripheral perfusion; the skin and the osteomuscular system were normal. Cardiac and pulmonary examination was unremarkable. The abdomen was flat, flaccid, and painless with normal bowel sounds; no enlarged viscera or tumor was

palpable. Neck stiffness was absent as well as any other sign of meningeal irritation. He was hospitalized for investigation, and kept presenting daily episodes of temperatures between 38°C and 40°C. The initial laboratory work-up is presented in Table 1.

Serologies were negative for HIV, hepatitis A, B, and C, toxoplasmosis, and rubella. EBV and cytomegalovirus were immunoglobulin G (IgG) positive, but immunoglobulin M (IgM) negative. A stool parasitological examination revealed the presence of *Giardia sp.* that was treated with a 5-day course of albendazole. The tuberculin skin test was negative as well as the research and culture for acid-fast bacilli in gastric aspirate. Transthoracic echodopplercardiogram and abdominal ultrasonographic examination were normal. Meanwhile, the child started complaining of mild, intermittent, and diffuse abdominal pain. An abdominal computed tomography (CT) was undertaken, which revealed multiple scattered nodular hypoattenuating lesions in the liver, measuring up to 1 cm, which were consistent with hepatic micro abscesses (Figure 1).

Wide spectrum antibiotic therapy was initiated (oxacillin, cefotaxime, and metronidazole). During hospitalization, the history of close contact with kittens was reported; therefore, with this new information, the CT images were reviewed and the diagnosis of CSD was thereafter highly considered. The indirect immunofluorescence assay test for *B. henselae*, on the twentieth day of clinical symptoms was positive:

Table 1. Initial laboratory work-up

Exam	Result	RV	Exam	Result	RV
Hemoglobin	10.8	11.5-13.5 g/dL	CRP	18	< 5 mg/L
Hematocrit	34.9	34-40%	ESR	50	< 15 mm/first hour
MCV	70.8	75-87 fl	ALT	28	< 43 U/L
RDW	13.3	< 14.9%	AST	34	< 35 U/L
Leukocytes	13,300	6-17.5 × 10 ³ /mm ³	TB/DB	0.17/0.07	1.2/0.2 mg/dL
Segmented	22	25-50%	ALP	148	< 390 U/L
Eosinophils	17	1-4%	γGT	29	< 30 U/L
Lymphocytes	48	50-56%	Albumin	3.9	3.0-5.0 g/dL
Monocytes	13	< 8%	Globulin	3	1.5-3.5 g/dL
Platelets	394	150-400 × 10 ³ /mm ³	LDH	249	120-246 U/L
INR	1.18	1.0	Uric acid	3.4	3.5-7.2 mg/dL

ALP = alkaline phosphatase; ALT = alanine aminotransferase; AST = aspartate aminotransferase; CRP = C-reactive protein; DB = direct bilirubin; γGT = gamma-glutamyl transferase; ESR = erythrocyte sedimentation rate; INR = international normalized ratio; LDH = lactate dehydrogenase; MCV = mean corpuscular volume; RDW = red cell redistribution width; RV = reference value; TB = total bilirubin.

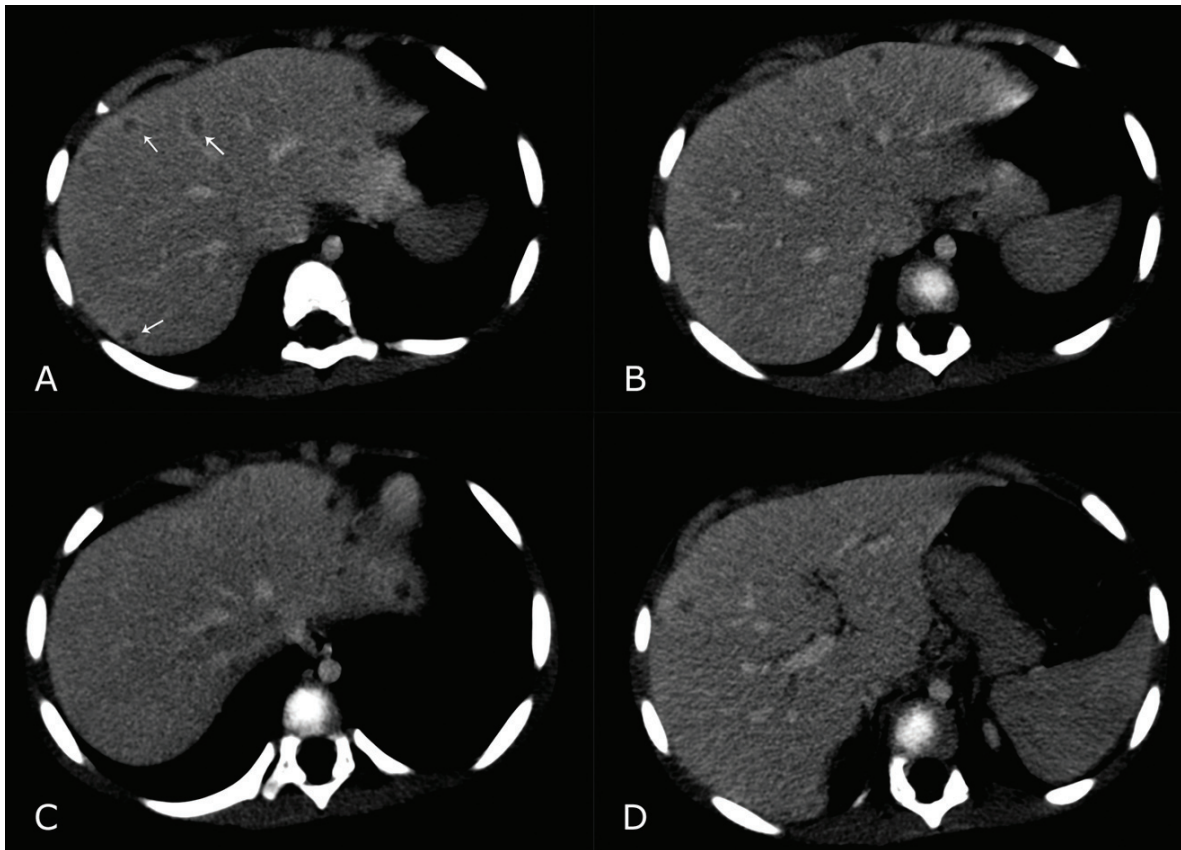


Figure 1. Abdominal CT after intravenous contrasted medium. Note in **A, B, C** and **D** – multiple hypoattenuating, small and round lesions – some of which are presented with a white arrow in **A**.

IgG > 1:256 and IgM > 1:128. Fever defervescence was noted 2 days after the initial antibiotics regimen (nonspecific for bartonellosis), which was maintained intravenously for 2 weeks and then replaced by clarithromycin orally for another 2-week period – a total of 4 weeks of treatment. After this period, the abdominal complaint was over.

DISCUSSION

In 1961, Petersdorf and Beeson¹ first described FUO in adults as a fever over 38.4°C, persisting for more than 3 weeks, without a defined cause, after at least 1 week of nosocomial intense study.⁷ In pediatrics, the most appropriate definition for FUO is still debatable; probably the definition suggested by Lorin and Feign⁸ is the most acceptable, which includes fever for more than 7 days accompanied by accurate anamnesis, and a normal physical examination and laboratory work-up. In pediatrics, FUO represents a remarkable demand for medical care. The clinician is in charge of running the proper evaluation, being aware of the most

common mistakes, including inadequate temperature documentation, failure to perform a careful medical history and a thorough physical examination, and the non-judicious or inappropriate use of the imaging and laboratory examinations.

Between 13% and 67% of the children⁹ will present spontaneous recovery without an etiological definition, and some will present atypical features of known diseases. During the FUO work-up, as observed in the case reported herein, abdominal imaging study by CT and/or ultrasonography followed the anamnesis, the physical examination, and the laboratory investigation.

In children, FUO comprises groups of illness; however, infectious diseases play the major role with 76.2% of cases in a prospective study.⁵

Bartonellosis should always be included in the differential diagnosis since it figures as the third cause of FUO.⁵ Even in the absence of lymphadenopathy, as observed in this report, we should remember the unusual forms of bartonellosis, which vary from 0.3% to 10%.¹⁰⁻¹² These forms include hepatic and splenic involvement with the presence of a granulomatous

necrotizing inflammatory process,¹² which commonly evolve as asymptomatic or with mild and diffuse abdominal pain.

The ultrasonography, which was the first imaging examination performed in our patient, exhibits a sensitivity of 83-87% for small hepatic lesions, compared with 94-100% of the CT, which, in turn, shows better accuracy after the use of an intravenous contrast medium.¹³ These hepatic and splenic nodules may be difficult to demonstrate because of their characteristics – sometimes homogeneous and hypodense and other times heterogeneous and blurred. Therefore, both imaging examinations are required, depending on the specific case.¹⁴ In the case reported herein, the CT was performed revealing hypoechogenic hepatic nodules consistent with the diagnosis of micro abscesses.

Hepatic abscesses are also an important cause of FUO. Among adults, polymicrobial abscesses represent half of the cases. In this setting *Escherichia coli*, *S. aureus*, *Klebsiella pneumoniae*, besides other aerobic and anaerobic agents, are identified.¹⁵ Among children, pyogenic liver abscess is more frequently caused by *S. aureus*, followed by amebic and fungal abscesses.¹⁶

Clinical features of CSD with hepatic involvement are somewhat varied, including high-grade fever, weight loss, and abdominal pain that ranges from mild to severe, predominantly in the right side. Hepatic lesions, smaller than 2 cm, are considered micro abscesses. Ultrasonography varies according to the stage of the disease;^{15,16} therefore, pyogenic hepatic micro abscesses may appear as hyperechogenic nodules at the beginning, but as the disease progresses they become distorted, hypoechogenic, and poorly defined areas.¹⁷ However, the CT images show multiple, small, well-delimited hypoattenuating lesions (also defined as hepatic granulomas), which, initially in our case, directed the diagnosis towards pyogenic liver abscesses.¹⁷

In developing countries, infectious diseases represent the most common etiology of hepatic granulomas. Most of them are epithelioid and some of them may show necrosis. Among them we highlight *B. henselae*, *Mycobacterium leprae*, *Rickettsia*, tularemia, *Listeria sp.*, Whipple disease, *Salmonella sp.* (including typhoid fever), syphilis, *Chlamydia*

sp., *Rhodococcus sp.*, *Yersinia sp.*, toxoplasmosis, *Candida spp.*, *Histoplasma sp.*, and *Aspergillus sp.*¹⁸ Schistosomiasis also presents hepatic granuloma, but in these cases, the inflammatory infiltration is rich in eosinophils, and generally is accompanied by fibrosis and portal hypertension.¹⁸

Fibrin-ring are an unusual form of granulomas associated with *Coxiella burnetii* infection, but may be found also in cytomegalovirus and EBV infections, salmonellosis, toxoplasmosis, erythematous systemic lupus, drug reactions (BCG, allopurinol, carbamazepine, chlorpromazine, diazepam, phenytoin, cephalexin, penicillin, oxacillin, isoniazid, aspirin, dimeticone, ranitidine, hydralazine, and hydrochlorothiazide, among others).¹⁸

Other causes of granulomas that should never be overlooked, include hepatitis C, which presents as a non-necrotizing epithelioid granuloma, and tuberculosis, mainly in the military form that typically presents as caseous granuloma with giant cells. *Mycobacterium avium* represent an important cause of granuloma in patients with immunosuppression.^{11,18}

Histologically, hepatic granulomas are characterized by a nodular aggregate of epithelial cells and macrophages, which are surrounded by mononuclear cells (mainly lymphocytes).¹⁸

B. henselae, the etiological agent of CSD, triggers a granulomatous reaction in the liver and constitutes a remarkable cause of FUO. The incidence of CSD is higher among children and adolescents, but may involve patients of any age. This Gram-negative bacillus is usually inoculated by a kitten scratch. Clinically, the disease is characterized by long-term fever, regional lymphadenopathy – usually in the upper limbs close to the bacteria inoculation. Disseminated disease, with visceral involvement, occurs in 5-10% of cases. In the abdomen, micro abscesses (measuring from 3 mm to 30 mm) can be found in the liver and spleen, even in the absence of hepatosplenomegaly. Diagnosis is reached through biopsy and or specific serological tests for *B. henselae*. Histological findings include proliferative vascular lesions and necrotizing granulomas.¹¹ Regarding the serologic evaluation, a prospective clinical controlled trial comprising 80 patients with CSD showed that laboratory tests, including IgM (ELISA) and IFA (immunofluorescence assay) exhibited the sensitivity ranging from 66 to 83%

when correlated with the clinical picture, and from 73 to 93% when correlated to the skin test. The specificity ranged from 98% for IFA and 95% for IgM.¹⁹

Our patient, after a thorough investigation, referred the contact with kittens before the onset of fever, which led us to consider the hypothesis of CSD and undergo a subsequent investigation with specific serology.

Usually, the granulomas on ultrasonographic examination present as hypoechogenic lesions varying from well-defined and homogeneous to heterogeneous and blurred patterns. The images on the abdominal CT show hypo or isoattenuating lesions. Nuclear magnetic resonance studies are few, but the scarce reports show low intensity nodules, enhanced after gadolinium infusion in T1 and high intensity nodules in T2. Calcifications may appear on the former hepatic lesions after months or years.^{20,21} In the case presented herein, the hepatic lesions were described as possible micro abscesses and therefore the treatment was driven towards this diagnosis. However, after the CSD diagnosis, the micro abscesses were considered as caused by the *Bartonella henselae* and the specific treatment was assumed.

The great majority of patients, who present the typical CSD with lymphadenopathy, have a self-limited course of the disease and do not require antibiotics. However, in the case of disseminated disease, antibiotics are often necessary. Currently, a 5-day course of azithromycin is 500 mg as the initial dose, followed by 250 mg daily for the remaining 4 days in children weighing more than 45 kg; or 10 mg/kg/day on the first day followed by 5 mg/kg/day on the four subsequent days, in smaller children. Other antimicrobials that show favorable results are rifampin, ciprofloxacin, gentamicin, and trimethoprim-sulfamethoxazole.

B. henselae shows *in vitro* sensitivity for G-penicillin (MIC 0.03-0.06), cephalosporins (MIC 0.12-0.5), oxacillin (MIC 1-2), aminoglycosides (MIC 0.12-0.25), tetracycline, clarithromycin (MIC 0.006-0.03), quinolones (MIC 0.25-1). *In vivo* studies permitting the routine use of these drugs are still lacking.^{22,23}

Our patient became afebrile 48 hours after the antibiotic regimen (oxacillin, cefotaxime, and metronidazole). In this case report, it remains doubtful

whether the *Bartonella sp* was sensitive to any of the administered antibiotics (since *in vitro* it shows a low MIC for cephalosporin) or if the disease would be self-limited without the need of the specific treatment.

Pyogenic micro abscesses and bartonellosis hepatic nodules may be misinterpreted by their similar clinical presentation and imaging examination. Since bartonellosis is an important cause of FUO, we consider a detailed anamnesis accompanied by epidemiological enquiry as essential to establish the correct diagnosis, and thereby permitting the appropriate treatment.

REFERENCES

1. Petersdorf RG, Beeson PB. Fever of unexplained origin: report of 100 cases. *Medicine*. 1961;40(1):1-30. <http://dx.doi.org/10.1097/00005792-196102000-00001>
2. Lambertucci JR. Febre. In: Lopez M, Laurentys-Medeiros J, editors. *Semiologia médica: as bases do diagnóstico clínico*. Rio de Janeiro: Revinter; 2004. p.66-77. Portuguese.
3. Batistela S, Guerreiro NP, Rossetto EG. Os motivos de procura pelo pronto-socorro pediátrico de um Hospital Universitário referidos pelos pais ou responsáveis. *Semina Ciênc Biol Saúde*. 2008;29(2):121-30. Portuguese. <http://dx.doi.org/10.5433/1679-0367.2008v29n2p121>
4. Lambertucci JR, Ávila RE, Voietta I. Febre de origem indeterminada em adultos. *Rev Soc Bras Med Trop*. 2005;38(6):507-13. PMID:16410928. Portuguese. <http://dx.doi.org/10.1590/S0037-86822005000600012>
5. Jacobs RF, Schutze GE. *Bartonella henselae* as a cause of prolonged fever and fever of unknown origin in children. *Clin Infect Dis*. 1998;26(1):80-4. <http://dx.doi.org/10.1086/516256>
6. Gilio AE. Febre de origem indeterminada. In: Gilio AE, Escobar AMUE, Grisi S, editors. *Pediatria geral: neonatologia, pediatria clínica, terapia intensiva*. São Paulo: Hospital Universitário da Universidade de São Paulo:Atheneu; 2011. p. 15-22. Portuguese.
7. Gartner JC Jr. Fever of unknown origin. *Adv Pediatr Infect Dis*. 1992;7:1-24. PMID:1616682.
8. Palazzi, DL. Approach to the child with fever of unknown origin. Topic 5993 Version 12. Waltham: UpToDate; 2013.
9. Akpede GO, Akenzua GI. Management of children with prolonged fever of unknown origin and difficulties in the management of fever of unknown origin in children in developing countries. *Pediatr Drugs*. 2001;3(4):247-62. <http://dx.doi.org/10.2165/00128072-200103040-00002>

10. Marsilia GM, La Mura A, Galdiero R, Galdiero E, Aloj G, Ragozzino A. Isolated hepatic involvement of cat scratch disease in immunocompetent adults: enhanced magnetic resonance imaging, pathological findings, and molecular analysis--two cases. *Int J Surg Pathol*. 2006;14(4):349-54. PMID:17041206. <http://dx.doi.org/10.1177/1066896906291780>
11. Klotz SA, Ianas V, Elliot SP. Cat scratch disease. *Am Fam Physician*. 2011;83(2):152-5. PMID:21243990.
12. Ventura A, Massei F, Not T, Massimetti M, Bussani R, Maggiore G. Systemic Bartonella henselae infection with hepatosplenic involvement. *J Pediatr Gastroenterol Nutr*. 1999;29(1):52-6. PMID:10400104. <http://dx.doi.org/10.1097/00005176-199907000-00014>
13. Kuster Filho ACC, Kruger MR, Pacheco AL, Souza Filho ZA. Abscessos hepáticos piogênicos: emprego dos recursos diagnósticos e terapêuticos. *Rev Col Bras Cir*. 1998;25(6):369-74. Portuguese. <http://dx.doi.org/10.1590/S0100-69911998000600003>
14. Hopkins KL, Simoneaux SF, Patrick LE, Wyly JB, Dalton MJ, Snitzer JA. Imaging manifestation of cat scratch disease. *Am J Roentgenol*. 1996;166(2):435-8. PMID:8553962. <http://dx.doi.org/10.2214/ajr.166.2.8553962>
15. Bonder A, Afdhal N. Evaluation of liver lesions. *Clin Liver Dis*. 2012;16(2):271-83. PMID:22541698. <http://dx.doi.org/10.1016/j.cld.2012.03.001>
16. Mishra K, Basu S, Roychoudhury S, Kumar P. Liver abscess in children: an overview. *World J Pediatr*. 2010;6(3):210-6. PMID:20706820. <http://dx.doi.org/10.1007/s12519-010-0220-1>
17. Sharma D. Long-term follow-up of pyogenic liver abscess by ultrasound. *Eur J Radiol*. 2010;74(1):195-8. PMID:19217231. <http://dx.doi.org/10.1016/j.ejrad.2009.01.017>
18. Lagana SM, Moreira RK, Lefkowitz JH. Hepatic granulomas: pathogenesis and differential diagnosis. *Clin Liver Dis*. 2010;14(4):605-17. PMID:21055685. <http://dx.doi.org/10.1016/j.cld.2010.07.005>
19. Szalc-Kelly CM, Goral S, Perez-Perez GI, Perkins BA, Regnery RL, Edwards KM. Serologic responses to Bartonella and Afipia antigens in patients with Cat Scratch Disease. *Pediatrics*. 1995;96(6):1137-42. PMID:7491236.
20. Mortelé KJ, Segatto E, Ros PR. The infected liver: radiologic-pathologic correlation. *Radiographics*. 2004;24(4):937-55. PMID:15256619. <http://dx.doi.org/10.1148/rg.244035719>
21. Stuart SM, Nowicki MJ. Radiological case of the month: cat-scratch disease with hepatic and splenic involvement. *Arch Pediatr Adolesc Med*. 1998;152(8):823-4. PMID:9701150.
22. Conrad DA. Treatment of cat-scratch disease. *Curr Opin Pediatr*. 2001;13(1):56-9. PMID:11176245. <http://dx.doi.org/10.1097/00008480-200102000-00010>
23. Maurin M, Gasquet S, Ducco C, Raoult D. MICs of 28 antibiotic compounds for 14 *Bartonella* (Formerly *Rochalimaea*) isolates. *Antimicrob Agents Chemother*. 1995;39(11):2387-91. PMID:8585713 PMID:PMC162952. <http://dx.doi.org/10.1128/AAC.39.11.2387>

Conflict of interest: None

Submitted on: April 8, 2014

Accepted on: June 10, 2014

Correspondence

Divisão de Clínica Pediátrica

Hospital Universitário da Universidade de São Paulo

Av. Prof. Lineu Prestes, 2565 – Cidade Universitária – São Paulo/SP – Brazil

Cep 05508-000

Phone +55 (11) 3091-9404

E-mail angela@hu.usp.br