

## Descending necrotizing mediastinitis secondary to a dental infection

Edson Martins de Oliveira Junior<sup>a</sup>, Raphael Teixeira Moreira<sup>b</sup>, Tayguara Cerqueira Cavalcante<sup>c</sup>

Oliveira Junior EM, Moreira RT, Cavalcante TC. Descending necrotizing mediastinitis secondary to a dental infection. Autopsy Case Rep [Internet]. 2012;2(1):37-42. <http://dx.doi.org/10.4322/acr.2012.006>

### ABSTRACT

Descending necrotizing mediastinitis is a rare type of deep infection of the soft tissues of the face, originating from cervical and oral infections, typically dental infections. It is associated with high mortality, due to its high invasive potential and the fact that the diagnosis is often delayed. We report the case of a 42-year-old female patient presenting with severe trismus, fever, purulent intraoral drainage, dysphagia, and dysphonia, accompanied by edema and redness in the cervical region. She was diagnosed with necrotizing descending mediastinitis secondary to a dental infection after the extraction of a mandibular third molar. The patient underwent surgical drainage and intravenous antibiotic therapy. Despite the development of septicemia, the evolution was favorable and the patient was discharged on post-admission day 20. Early and accurate diagnosis, together with prompt treatment, is imperative for better outcomes in this rare condition.

**Keywords:** Mediastinitis; Therapeutics.

### INTRODUCTION

Mediastinitis is defined as an inflammation of the mediastinal tissue.<sup>1,2</sup> It is unusual for mediastinitis to be caused by dental infections, given that the infection would have to traverse the superficial and deep fasciae of the face, as well as the cervical fascia.<sup>3</sup>

Mediastinitis is often caused by esophageal perforation or infection of the sternum after cardiac surgery. In rare cases, mediastinitis can arise after Ludwig's angina or can be secondary to deep neck space infection, in general, due to the infection of the second or third inferior molar.<sup>4,5</sup> Such cases are

classified as descending necrotizing mediastinitis, and the clinical picture can be severe.<sup>6</sup>

Descending necrotizing mediastinitis primarily affects young adults (mean age, 36 years), and 86% of the patients are men.<sup>7</sup> It is polymicrobial in origin,<sup>8</sup> the most common etiological agents being *Staphylococcus aureus*, *Staphylococcus epidermidis*, *Pseudomonas* sp. and *Escherichia coli*.<sup>9,10</sup> Gram-positive bacilli, such as *Eubacterium* and *Lactobacillus* spp., can also be involved.<sup>11</sup> Descending necrotizing mediastinitis is a serious condition, with mortality rates as high as 40%.<sup>8</sup>

<sup>a</sup> Department of Dentistry - Hospital Universitário - Universidade de São Paulo, São Paulo/SP - Brazil.

<sup>b</sup> Department of Dentistry - Hospital Universitário Oswaldo Cruz, Universidade de Pernambuco, Recife/PE - Brazil.

<sup>c</sup> Department of Dentistry - Hospital Obras Sociais da Irmã Dulce, Salvador/BA - Brazil.

The clinical evaluation of a suspected patient should include an analysis of the family history, the duration of symptoms, and any previous treatment. In assessing the local and regional extent of the infection, the following signs and symptoms should be taken into consideration: trismus, stiffness, fistula formation, abscess formation, airway involvement, and dysphagia.

Descending necrotizing mediastinitis can be characterized through a variety of imaging techniques, including periapical radiography of the maxillofacial complex and panoramic radiography of the maxilla, as well as chest X-ray for the evaluation of pulmonary impairment and X-ray of the cervical region in order to identify edema of the neck, a condition that can, depending on the degree, compress the upper airways.<sup>11</sup> Radiography can reveal an increase in the size of the mediastinum. The use of computed tomography (CT) is essential and has value not only as a means of confirming the diagnosis but also for informing decisions regarding the surgical strategy.<sup>12,13</sup>

Laboratory tests should be requested, because they provide an overview of the systemic involvement. White cell counts, red cell counts, and blood glucose should be evaluated, because they have a direct effect on the treatment. Diagnostic errors can allow the infection to spread to adjacent spaces, worsening the clinical course.<sup>14</sup>

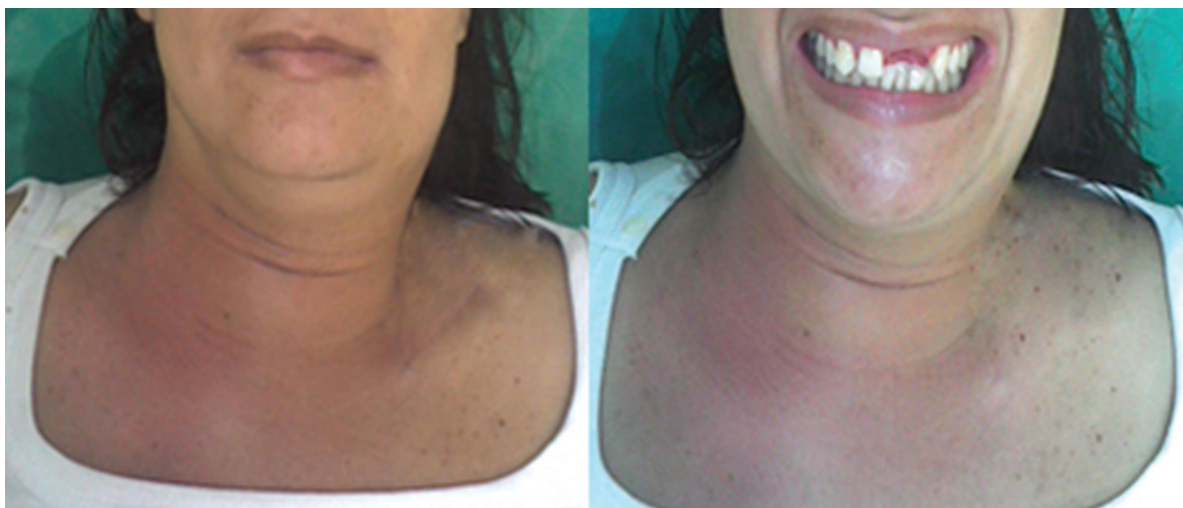Because it is a severe form of infection, descending necrotizing mediastinitis requires early diagnosis and surgical treatment to reduce mortality. The emergency treatment should be initiated as

early as possible and should consist of transcervical mediastinal drainage and administration of intravenous antibiotics.

## CASE REPORT

A 42-year-old White female sought treatment at the Maxillofacial Trauma Clinic of the Hospital de Pronto Socorro de Maceió – Alagoas (AL – Brazil), complaining of a 10-day history of difficulty in opening her mouth, which prevented her from eating, as well as pus in her mouth, fever, and headache. The patient reported that her third left inferior molar (tooth 38) had been extracted 13 days earlier. The initial clinical examination revealed severe trismus, limited side-to-side head movement, intense halitosis, as well as a large quantity of purulent secretion, accompanied by volumetric changes and skin redness of the lower third of the face, neck, and of the upper thorax (Figures 1 and 2). The patient said that she was using antibiotics (amoxicillin at admission, and that she had also previously used azithromycin and metronidazole, for less than 3 days in both cases. An emergency CT scan showed disseminated infection, originating in the left submandibular space and extending from the pretracheal fascia space to the mediastinum (Figure 3). On the basis of the clinical and CT findings, the patient was diagnosed with a dental infection that had spread to the neck and mediastinum.

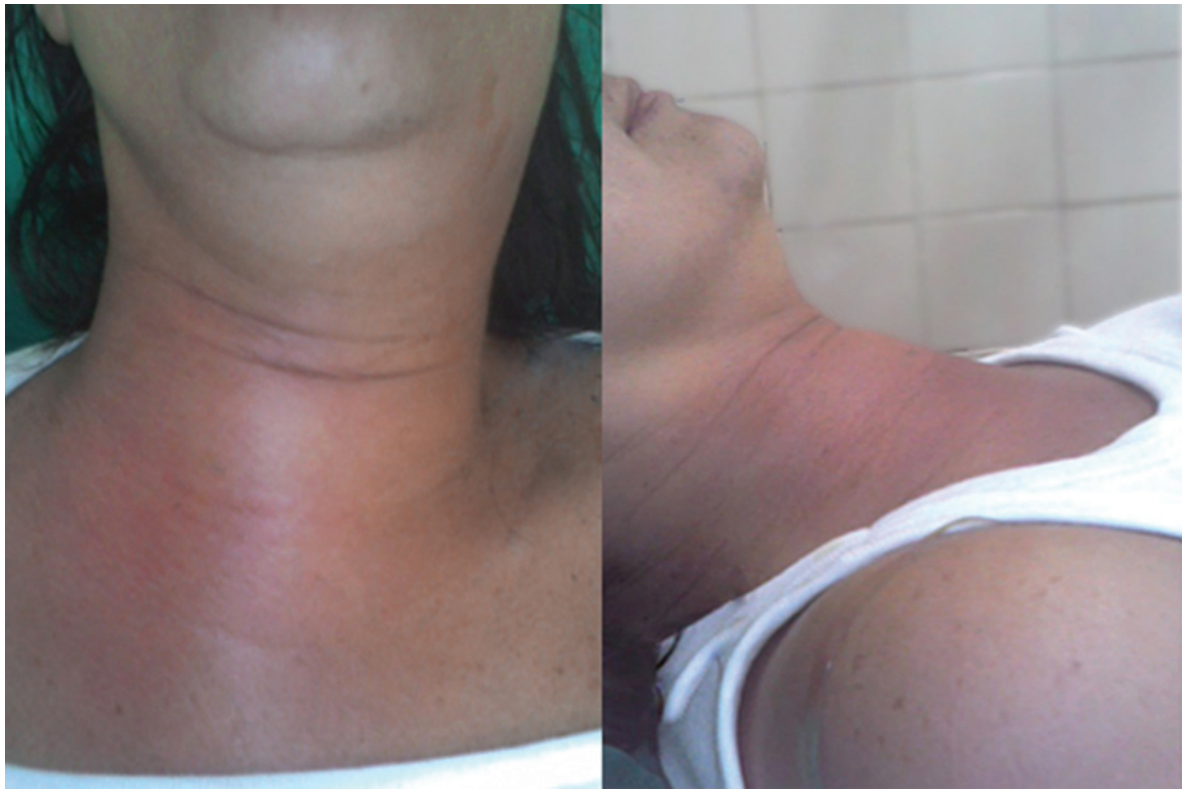The patient underwent surgery (neck incision and drainage) under general anesthesia. During the nasotracheal intubation procedure, the patient



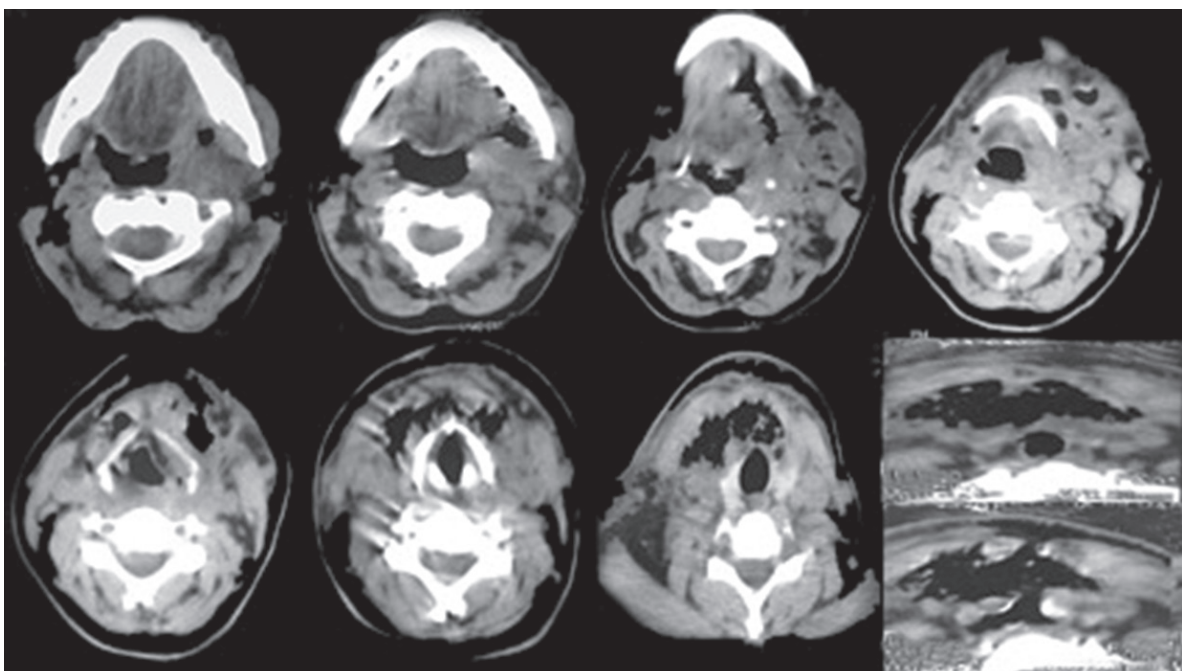
**Figure 1** – Appearance of the patient during the initial treatment. Patient, without the prosthesis, with trismus while attempting to open her mouth.

aspirated pus from the oral cavity, progressing to asphyxiation, necessitating emergency tracheostomy, hampered by the large amount of pus in the cervical region. Drainage was performed by cervical bilateral extension of the incision to tracheostomy. The patient was admitted to the ICU and was treated intravenously for nine days with

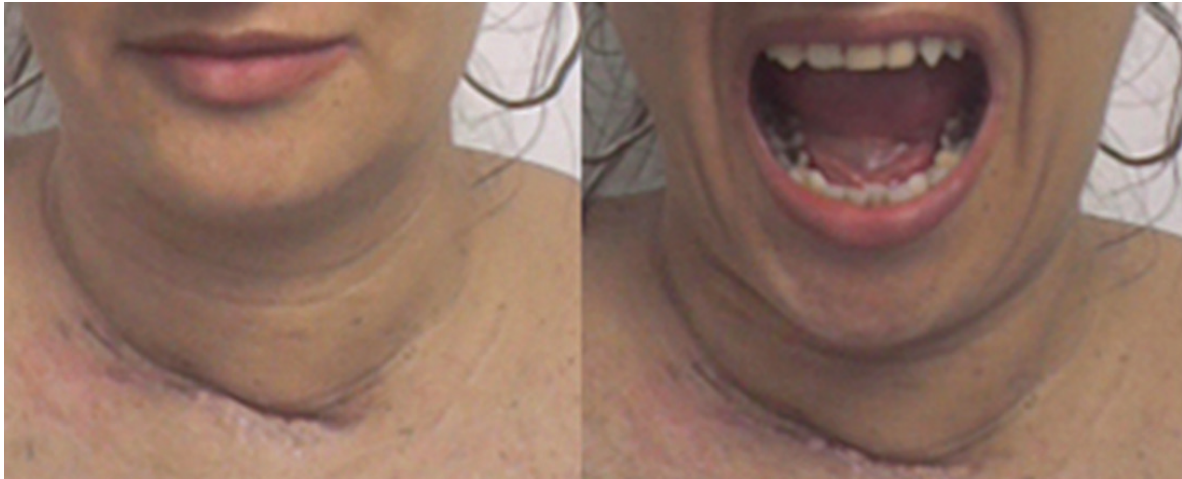ceftriaxone (1 g every 12 hours), metronidazole (500 mg every 8 hours) and gentamicin (80 mg every 8 hours). After discharge from the ICU, the patient was hospitalized for two days in the infirmary until the removal of the tracheostomy tube, after which she was discharged to outpatient follow-up. Fifty-four days later, the patient underwent repair of



**Figure 2** – Static physical examination (anterior and profile). Note the swelling and redness of the neck.



**Figure 3** – Axial CT images in the craniocaudal dimension, suggestive of the presence of gas produced at the site of infection dissecting the right pterygoid space and the pretracheal fascia.



**Figure 4** – Patient on post-admission day 41. Mouth opening to a near-normal extent (34 mm). Note the repair of the tracheal fistula.

the tracheal fistula (Figure 4) and was discharged on post-procedure day 7.

## DISCUSSION

In the past, severe cervical infections, such as mediastinitis, were conditions that carried a significant risk of death. With improvements in antibiotic therapy, diagnostic techniques, and early surgical intervention, mortality rates have fallen significantly. However, in the case of mediastinitis, the mortality rate remains at approximately 40%.<sup>8,15</sup> Although the case reported here did not evolve to death, the patient developed septicemia and required 2 weeks of treatment in the ICU.

In cases of descending necrotizing mediastinitis, the infection originates in the fasciae of the head and neck, infiltrating into the mediastinum via the cervical fasciae, facilitated by gravity, respiration, and negative intrathoracic pressure. The most common anatomical pathway by which the infection spreads is the lateral pharyngeal space to the retrovisceral space (retropharyngeal) (implicated in 70% of cases), thereby extending inferiorly to the mediastinum.<sup>15-17</sup> In the case reported here, the mediastinal infection developed after the extraction of a third molar and rapidly progressed to the superficial and deep fasciae of the face, severely affecting the deep layers of the cervical fascia before arriving at the mediastinum.

Most cases of descending necrotizing mediastinitis occur as a postoperative complication of cardiovascular surgery.<sup>18,19</sup> However, other

causes are known, among which are the extent of the head and neck infection.<sup>20,21</sup> Dental infections are the most common of such infections.<sup>10,17,22</sup>

The diagnosis of a deep neck infection can be difficult to make on the basis of history-taking and physical examination alone, especially in patients who have previously used antibiotics. Local signs such as edema, fluctuation, hyperemia, and pain might not be evident. Physical examination can reveal fever and neck swelling. In addition, patients with a deep neck infection typically present with dehydration, sore throat, dysphagia, dysphonia (impaired glottal function), dyspnea and trismus.<sup>6</sup> In the case under discussion here, the patient presented with fever, severe trismus, difficulty in swallowing, and difficulty in speaking, all of which are clear clinical signs of infection. The skin on the anterior neck was red and swollen.

The microbiology of descending necrotizing mediastinitis is complex, 88% of cultures containing more than two microorganisms; 94% containing anaerobic bacteria only; and 52% containing anaerobic and aerobic bacteria.<sup>23</sup> Chief among such microorganisms are *Staphylococcus aureus*, *Staphylococcus epidermidis*, *Pseudomonas* sp. and *E. coli*.<sup>9,10</sup> In the case presented here, culture and sensitivity testing were not performed at admission. Because bacterial agents other than the normal oral flora are rarely found in cases of dental infection, the recommended antibiotic therapy can be initiated before the result of the microbial culture is known.<sup>24</sup>

Imaging studies are essential for assessing the presence of pus, the neck spaces affected, and the potential complications, as well as for planning

the treatment strategy. The most widely used imaging technique is CT,<sup>12</sup> because it accurately shows the early involvement of the mediastinum, allowing the ideal surgical site to be identified.<sup>15</sup>

The diagnostic criteria for descending necrotizing mediastinitis are as follows<sup>25</sup> evidence of oropharyngeal infection; radiographic features characteristic of mediastinitis; documented infection in the intra-operative period or post-mortem evaluation; and communication between the oropharyngeal process and the mediastinum.

The primary treatment for descending necrotizing mediastinitis is the combination of antibiotics and drainage. The use of intravenous broad-spectrum antibiotics is not effective without adequate cervical drainage, extensive debridement and excision of the necrotic tissue. In most cases, repeated cervical drainage is required due to persistent infection.<sup>6</sup> In the case reported here, the patient was treated with a combination of antibiotic therapy comprising ceftriaxone (2 g every 12 hours), metronidazole (500 mg every 8 hours) and gentamicin (80 mg every 8 hours) and surgical drainage. Patients with descending necrotizing mediastinitis are typically treated with a broad-spectrum antibiotic in order to target gram-positive, gram-negative, and anaerobic bacteria.<sup>26</sup>

The surgical approaches to cervical drainage vary according to the location, extent, and degree of the infection.<sup>6,26,27</sup> In our case, the infection was located in the upper mediastinum and we opted for high transcervical mediastinal drainage.

The prognosis of descending necrotizing mediastinitis is poor, the high mortality rate (40-50%) having changed little over time. The results depend on the degree of infection and the presence of pre-existing systemic diseases, such as HIV and diabetes.<sup>28</sup> The causes of death are various, including septic shock, respiratory failure, and gastrointestinal bleeding.<sup>29</sup>

## CONCLUSION

Mediastinal infection can originate from the extraction of a third molar, with rapid progression through the superficial and deep fasciae of the face, as well as into the deep layers of the cervical fascia. This very aggressive form of mediastinitis with a high mortality rate imposes a fast diagnostic approach and combined therapy with antibiotics and drainage.

## REFERENCES

1. Macrí P, Jiménez MF, Novoa N, Varela GA. Descriptive of a series of patients diagnosed with acute mediastinitis. *Arch Bronconeumol*. 2003;39(9):428-30. PMID:12975075.
2. Souza VC, Freire ANM, Tavares-Neto, J. Mediastinite pós-esternotomia longitudinal para cirurgia cardíaca: 10 anos de análise. *Rev Bras Cir Cardiovasc*. 2002;17(3):266-70. Portuguese. <http://dx.doi.org/10.1590/S0102-7638200200300012>
3. Peterson JL, Ellis III E, Hupp JR, Tucker MR. *Cirurgia oral e maxilo-facial contemporânea*. 4th ed. Rio de Janeiro: Elsevier; 2005. Portuguese.
4. Brommelstroet M, Rosa JFT, Boscardim PCB, Schmidlin CA, Shibata S. Mediastinite descendente necrosante pós angina de Ludwig. *J Pneumologia*. 2001;27(5):269-71. Portuguese.
5. Conto F, Rettore C, Bertoli MM, Rohden RM. Mediastinite de origem odontogênica. *Rev Bras Cir Buco-Maxilo-Facial*. 2011;11(2):27-34. Portuguese.
6. Marty-Ané CH, Alauzen M, Alric P, Serres-Cousine O, Mary H. Descending necrotizing mediastinitis. *J Thorac Cardiovasc Surg*. 1994;107(1):55-61. PMID:8283919.
7. Moriwaki Y, Sugiyama M, Matsuda G, et al. Approach for drainage of descending necrotizing mediastinitis on the basis of the extending progression from deep neck infection to mediastinitis. *J Trauma*. 2002;53(1):112-6. <http://dx.doi.org/10.1097/00005373-200207000-00023>
8. Prado R, Salim M. *Cirurgia bucomaxilofacial: diagnóstico e tratamento*. Rio de Janeiro: Medsi; 2004. Portuguese.
9. Sampaio DT, Alves JCR, Silva AF, et al. Mediastinite em cirurgia cardíaca: tratamento com epíloon. *Rev Bras Cir Cardiovasc*. 2000;15(1):23-31. Portuguese.
10. Sancho LM, Minamoto H, Fernandez A, Sennes LU, Jatene FB. Descending necrotizing mediastinitis: a retrospective surgical experience. *Eur J Cardiothorac Surg*. 1999;16(2):200-5. [http://dx.doi.org/10.1016/S1010-7940\(99\)00168-2](http://dx.doi.org/10.1016/S1010-7940(99)00168-2)
11. Vasconcelos BCE, Cauás M, Albert DGM, Nascimento GFJ, Holanda GZ. Disseminação de infecção odontogênica através das fascias cervicais profundas. *Rev Cir Traumat Buco-maxilo-facial*. 2002;2(1):21-5. Portuguese.
12. Hueb MM, Borges LM, Oliveira LR. Angina de Ludwig: tratamento cirúrgico minimamente invasivo e guiado por ultra-sonografia cervical. *Arq Int Otorrinolaringol*. 2004;8(3):181-7. Portuguese.
13. Kaga K, Hida Y, Hirano S. Descending necrotizing mediastinitis. *Kyobu Geka*. 2011;64(8):752-7. PMID:21916190.

14. Pádua JM, Rocha LB, Lia RCC, Pietro RCLR, Fusco-Almeida AM. Disseminação de infecção purulenta envolvendo segundo e terceiro molares inferiores - relato de caso clínico. *BCI*. 2000;7(25):29-32. Portuguese.
15. Wheatley MJ, Stirling MC, Kirsh MM, Gago O, Orringer MB. Descending necrotizing mediastinitis: transcervical drainage is not enough. *Ann Thorac Surg*. 1990;49(5):780-4. [http://dx.doi.org/10.1016/0003-4975\(90\)90022-X](http://dx.doi.org/10.1016/0003-4975(90)90022-X)
16. Takao M, Ido M, Hamaguchi K, Chikusa H, Namikawa S, Kusagawa M. Descending necrotizing mediastinitis secondary to a retropharyngeal abscess. *Eur Respir J*. 1994;7(9):1716-8. PMID:7995405. <http://dx.doi.org/10.1183/09031936.94.07091716>
17. Suga A, Inoue Y, Takeichi H, Yamada S, Iwazaki M. A case of an elderly patient treated for descending necrotizing mediastinitis. *Gen Thorac Cardiovasc Surg*. 2011;59(9):623-6. PMID:22231792. <http://dx.doi.org/10.1007/s11748-010-0741-5>
18. El Oakley RM, Wright JE. Postoperative mediastinitis: classification and management. *Ann Thorac Surg*. 1996;61(3):1030-6. [http://dx.doi.org/10.1016/0003-4975\(95\)01035-1](http://dx.doi.org/10.1016/0003-4975(95)01035-1)
19. Callister ME, Wall RA. Descending necrotizing mediastinitis caused by group A streptococcus (serotype M1T1). *Scand J Infect Dis*. 2001;33(10):771-2. PMID:11728046. <http://dx.doi.org/10.1080/003655401317074608>
20. Sato S, Kajiyama Y, Kuniyasu T, et al. Successfully treated case of cervical abscess and mediastinitis due to esophageal perforation after gastrointestinal endoscopy. *Dis Esophagus*. 2002;15(3):250-2. PMID:12445000. <http://dx.doi.org/10.1046/j.1442-2050.2002.00253.x>
21. Von Rahden BH, Feith M, Dittler HJ, Stein HJ. Cervical esophageal perforation with severe mediastinitis due to an impacted dental prosthesis. *Dis Esophagus*. 2002;15(4):340-4. PMID:12472485. <http://dx.doi.org/10.1046/j.1442-2050.2002.00290.x>
22. Mitjans MS, Sanchís JB, Padro XB, et al. Descending necrotizing mediastinitis. *Int Surg*. 2000;85(4):331-5. PMID:11589602.
23. Chow AW. Life threatening infections of the head and neck. *Clin Infect Dis*. 1992;14(5):991-1002. PMID:1600027. <http://dx.doi.org/10.1093/clinids/14.5.991>
24. Dembo JB. *Emergência em odontologia*. Rio de Janeiro: Medsi; 1998. Portuguese.
25. Estrera AS, Lanay MJ, Grisham JM. Descending necrotizing mediastinitis. *Surg Gynecol Obstet*. 1983;157(6):545-52. PMID:6648776.
26. Fatureto MC, Neves-Junior MA, Santana TC. Mediastinite aguda: análise retrospectiva de 21 casos. *J Bras Pneumol*. 2005;31(4):307-11. Portuguese. <http://dx.doi.org/10.1590/S1806-37132005000400007>
27. Brunelli A, Sabbatini A, Catalini G, Fianchini A. Descending necrotizing mediastinitis: cervicotomy or thoracotomy. *J Thorac Cardiovasc Surg*. 1996;111(2):485-6. [http://dx.doi.org/10.1016/S0022-5223\(96\)70460-9](http://dx.doi.org/10.1016/S0022-5223(96)70460-9)
28. Cirino LMI, Elias FM, Almeida JLJ. Descending mediastinitis: a review. *São Paulo Med J*. 2006;124(5):285-90. PMID:17262162. <http://dx.doi.org/10.1590/S1516-31802006000500011>
29. Novellas S, Kechabtia K, Chevallier P, Sedat J, Bruneton JN. Descending necrotizing mediastinitis: a rare pathology to keep in mind. *Clin Imaging*. 2005;29(2):138-40. PMID:15752971. <http://dx.doi.org/10.1016/j.clinimag.2004.10.001>

**Conflict of interest:** None

**Submitted on:** 23<sup>th</sup> December 2011

**Accept on:** 30<sup>th</sup> January 2012

**Correspondence:** Divisão de Odontologia

Av. Prof. Lineu Prestes, 2565 – Cidade Universitária – São Paulo/SP – Brazil

CEP: 05508-000 – Phone: +55 (11) 3091-9290

E-mail: jr.odonto@gmail.com