

## Pulmonary agenesis and respiratory failure in childhood

Paula Vanessa Valverde Dinamarco<sup>a</sup>, Cesar Cilento Ponce<sup>a</sup>

Dinamarco PVV, Ponce CC. Pulmonary agenesis and respiratory failure in childhood. *Autopsy Case Rep* [Internet]. 2015; 5(1):29-32. <http://dx.doi.org/10.4322/acr.2014.046>

### ABSTRACT

Pulmonary agenesis (PA) is a rare congenital anomaly, which may be unilateral or bilateral. Unilateral PA may be associated with nonspecific respiratory symptoms. We report the case of 5-month-old infant who presented a normal development until the age of 4 months when a respiratory infection caused an acute respiratory distress syndrome with a fatal outcome. The autopsy findings depicted the right lung agenesis without any other concomitant malformation. Although respiratory symptoms represent frequent complaints in pediatrics, the aim of this study is not only to draw attention to the unilateral pulmonary agenesis as a possible underlying malformation in children who present recurrent and severe respiratory symptoms, but also to report a case diagnosed at autopsy.

### Keywords

Lung agenesis; Respiratory Insufficiency; Autopsy.

### INTRODUCTION

Pulmonary agenesis is an extremely rare congenital anomaly defined as a complete absence of the lung parenchyma, bronchus, and pulmonary vessels.<sup>1</sup> This anomaly was first discovered accidentally by De Pozze (1673) during the autopsy of an adult woman.<sup>2,3</sup>

The estimated prevalence is 24–34 per 1,000,000 live births, and 1 per 10,000–15,000 autopsies with a slight preponderance of females.<sup>4</sup> The etiology remains unknown, but its pathogenesis may be associated with genetic factors, such as the duplication of the distal part of the upper arm of chromosome 2, viral factors, or vitamin A deficits.<sup>5-6</sup>

In normal development, the embryonic phase begins during the fourth week of gestation with the formation of the respiratory diverticulum from the ventral wall of the primitive foregut.<sup>7</sup> It is possible that

pulmonary agenesis occurs due to the failure of the bronchial analogue to divide equally between the two lung buds. If this balance is not established, one side will develop normally while the other side will fail to develop and will lead to pulmonary agenesis/aplasia or pulmonary hypoplasia.<sup>4</sup>

Pulmonary agenesis is often associated with anomalies in the cardiovascular, gastrointestinal, genitourinary, or musculoskeletal systems.<sup>1,2-4,5</sup> Both lungs are equally affected but right lung agenesis shows worse prognosis.<sup>3,5</sup>

In the absence of other malformations, unilateral pulmonary agenesis is compatible with normal life, but is often associated with severe respiratory infections during childhood, which is associated with high mortality rates.<sup>4,8</sup>

<sup>a</sup> Office of the Chief Medical Examiner, Santos/SP - Brazil.



## CASE REPORT

A 5-month-old white female patient was brought to the hospital with severe respiratory distress syndrome. She was born at term and her mother had no remarkable past medical or obstetric history. The patient developed normally until the age of 4 months. At admission, the child presented with cough, fever, and dyspnea. The physical examination revealed tachypnea with subcostal and intercostal retractions. Breath sounds were absent in the right hemithorax on pulmonary auscultation.

A plain chest x-ray showed a homogeneous opacity of the entire right hemithorax with cardiac displacement to the right and left lung hyperinflation. The working diagnosis was bacterial pneumonia (Figure 1). The patient was treated with intravenous fluids, oxygen, and antibiotics. The hospital stay was characterized by progressive worsening of clinical parameters in the following 24 hours and the child died due to irreversible cardiorespiratory arrest.

Permission for autopsy was granted and an autopsy was performed. The thoracic cavity revealed a deviation and of the mediastinal structures to the right hemithorax, and hyperinflation of the left lung.

A thorough dissection of the thoracic organs showed the absence of the right lung, right bronchus, and right pulmonary vasculature. The displaced heart showed normal anatomic relationship with the great arteries. No other cardiac or systemic malformations (Figure 2) were found.

A single pulmonary artery was responsible for the left lung perfusion, and an obliterated ductus arteriosus was present (Figure 3).

Histological sections performed of the left lung, stained with hematoxylin and eosin (H&E) and Masson's trichrome, revealed interstitial inflammatory infiltrate composed of lymphocytes and macrophages associated with intense edema and numerous macrophages in the alveolar spaces consistent with interstitial pneumonia, felt to be a contributing factor for the child's demise (Figure 4).

## DISCUSSION

According to the classification, pulmonary agenesis was divided into three groups: Type 1 – Agenesis: complete absence of the lung, bronchus, and vascular supply of the affected side; Type 2 – Aplasia:

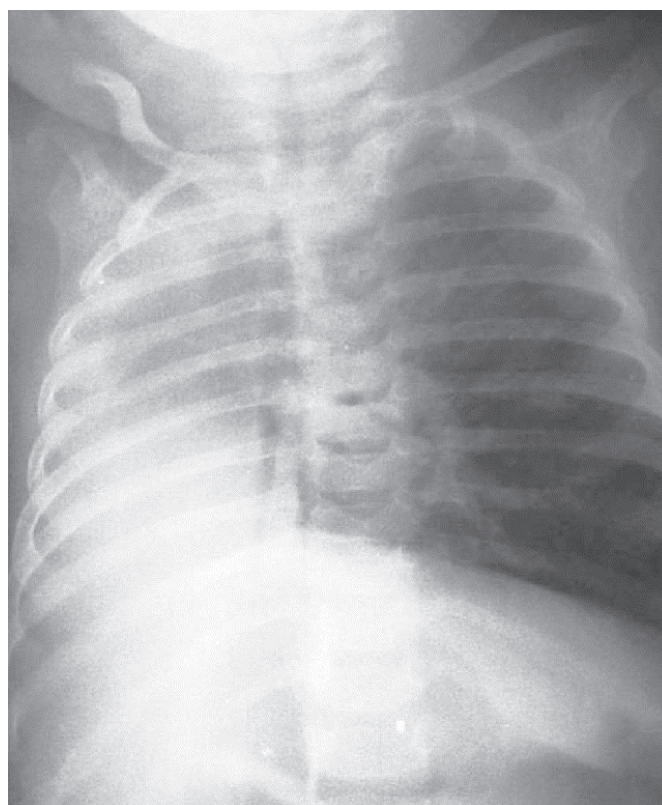
rudimentary bronchus with complete absence of the lung; Type 3 – Hypoplasia: a variable amount of the bronchial tree, lung parenchyma, and blood vessels.<sup>9</sup> The case reported herein can be classified as Type 1, because of the complete absence of vessels, bronchus, and right lung parenchyma.

In unilateral lung agenesis, the trachea extends directly into the main bronchus of the normally developed lung, and respiratory distress usually occurs due to inflammation and the retention of bronchial secretions.<sup>4</sup>

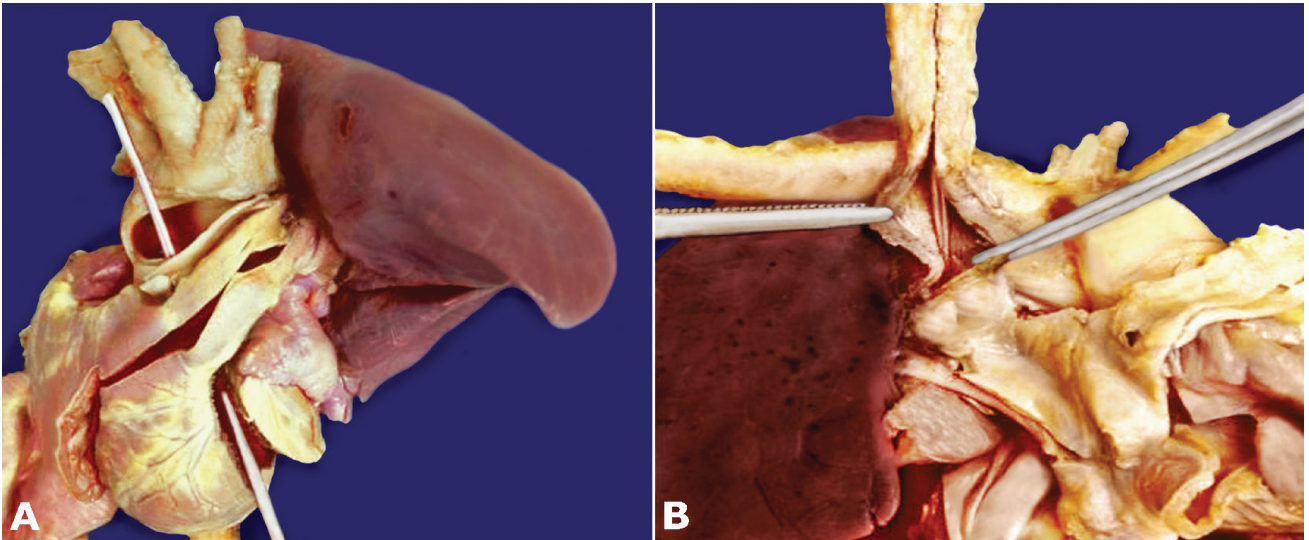
Right lung agenesis is usually associated with the displacement of the heart and mediastinum rightwards accompanied by a distortion of the bronchial and vascular structures, which worsens the prognosis.<sup>10</sup>

Although the specificity and sensitivity of fetal ultrasound has substantially improved in the last 20 years,<sup>11</sup> diagnosis of isolated pulmonary agenesis is quite often challenging during prenatal routine examination.

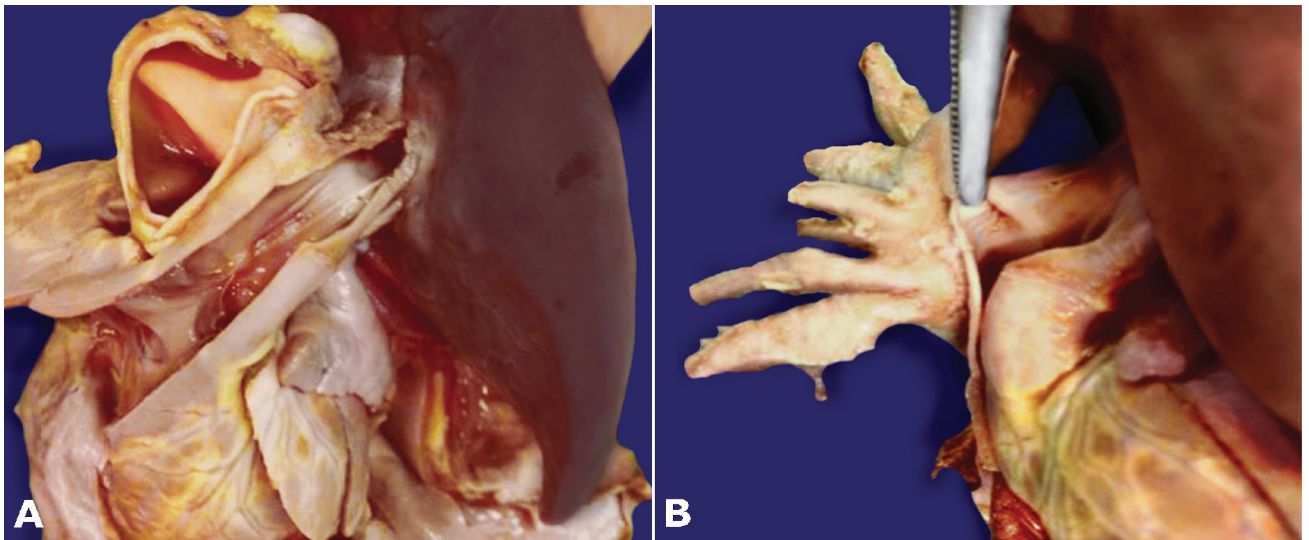
The clinical presentation of the disease is quite variable. In some cases, respiratory distress syndrome is present at birth, while, in other cases, the patients remain asymptomatic until adulthood when they are



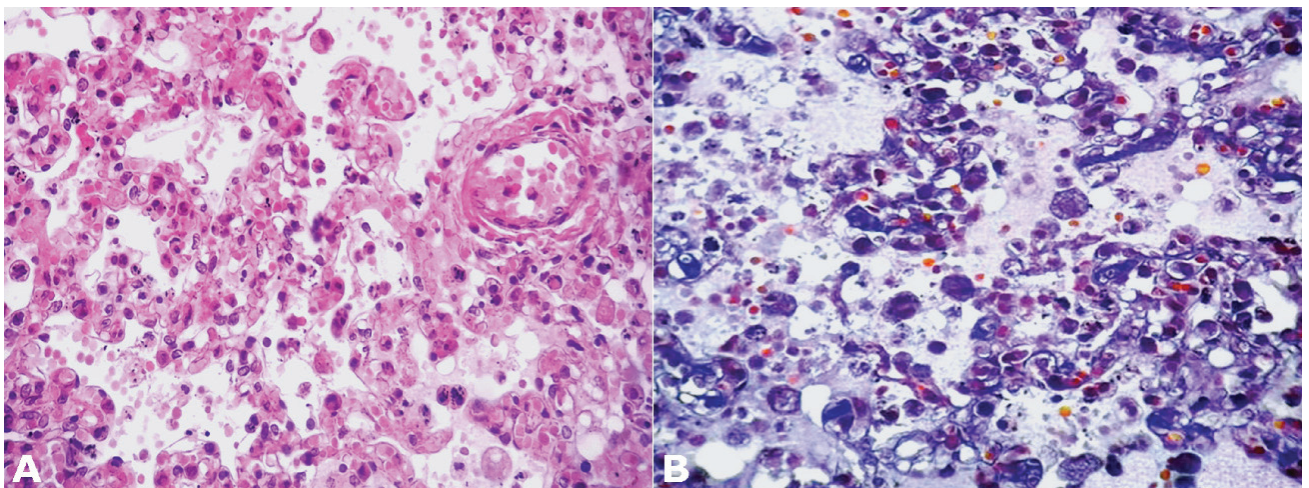
**Figure 1.** Chest x-ray showing a right hemithorax opacification and left lung vicariance. Note the rightward deviation of the mediastinal structures.



**Figure 2.** **A** - Front view of the thoracic organs. Note a single pulmonary artery perfusing the left lung and lack of the right lung. **B** - Posterior view characterized by the complete absence of the right main bronchus and lung.



**Figure 3.** **A** - Non-bifurcate trunk of the pulmonary artery. **B** - Note at the tip of the forceps the obliterated ductus arteriosus.



**Figure 4.** Photomicrography of the lung. **A** - Interstitial inflammatory infiltration and alveolar edema (H&E, 400X). **B** - The presence of numerous macrophages and edema in the alveolar spaces (Masson's Trichrome, 400X).

incidentally diagnosed.<sup>6</sup> More than 50% of children with lung agenesis die within 5 years of birth. Respiratory tract infections are the greatest risk for these individuals.<sup>4</sup> In our case, the lung microscopic findings revealed mononuclear cells composed of mature lymphocytes and macrophages in the septa and edema in the alveolar spaces, features of interstitial pneumonitis. Unfortunately, the respiratory failure rapidly progressed to a fatal outcome.

In children with recurrent respiratory infections if no improvement is observed in the plain chest x-ray imaging, contrasted thoracic computed tomography is recommended in order to establish an accurate diagnosis of infection or a possible malformation.

Asymptomatic patients do not require intervention, especially in the absence of associated anomalies.<sup>6</sup> However, pulmonary infection or other lung diseases should be treated early.<sup>4,6</sup>

When signs of respiratory failure are due to the torsion and compression of the trachea by the rotation of the heart, mediastinum, and displacement of the aortic arch, diaphragmatic translocation and aortopexy are indicated.<sup>8</sup>

Although pulmonary agenesis is a rare congenital anomaly, the pursuit of an accurate diagnosis is fundamental for prenatal counseling and better medical management to reduce mortality and improve prognosis.

## REFERENCES

1. Sharma S, Kumar S, Yaduvanshi D, Chauhan D. Isolated unilateral pulmonary agenesis. *Indian Pediatr.* 2005;42(2):170-2. PMID:15767714.

2. Kisku KH, Panigrahi MK, Sudhakar R, Nagarajan A, Ravikumar R, Daniel JR. Agenesis of lung: a report of two cases. *Lung India.* 2008;25(1):28-30. <http://dx.doi.org/10.4103/0970-2113.44136>. PMID:20396661
3. De Pozze S, Brescia MA, Amermon EE, Sharma KK. Agenesis of the Left Lung. *Arch Pediatr.* 1960;77:485-90.
4. Kumar B, Kandpal DK, Sharma C, Sinha DD. Right lung agenesis. *Afr J Paediatr Surg.* 2008;5(2):102-4. <http://dx.doi.org/10.4103/0189-6725.44189>. PMID:19858680
5. Say B, Carpenter NJ, Giacoia G, Jegathesan S. Agenesis of the lung associated with a chromosome abnormality (46,XX,2p+). *J Med Genet.* 1980;17(6):477-8. <http://dx.doi.org/10.1136/jmg.17.6.477>. PMID:7205432
6. Malcon MC, Malcon CM, Cavada MN, Caruso PE, Real LF. Unilateral pulmonary agenesis. *J Bras Pneumol.* 2012;38(4):526-9. <http://dx.doi.org/10.1590/S1806-37132012000400016>. PMID:22964938
7. Biyyam DR, Chapman T, Ferguson MR, Deutsch G, Dighe MK. Congenital lung abnormalities: embryologic features, prenatal diagnosis, and postnatal radiologic-pathologic correlation. *Radiographics.* 2010;30(6):1721-38. <http://dx.doi.org/10.1148/rg.306105508>. PMID:21071385
8. Khurram MS, Rao SP, Vamshipriya A. Pulmonary agenesis: a case report with review of literature. *Qatar Med J.* 2013;2013(2):38-40. <http://dx.doi.org/10.5339/qmj.2013.14>. PMID:25003063
9. Bachh AA, Pulluri S, Beigh A, Raju C, Deshpande R. Pulmonary aplasia with unusual associations in a woman. *Iran J Med Sci.* 2014;39(2):148-51. PMID:24644386.
10. Chou AK, Huang SC, Chen SJ, et al. Unilateral lung agenesis: detrimental roles of surrounding vessels. *Pediatr Pulmonol.* 2007;42(3):242-8. <http://dx.doi.org/10.1002/ppul.20561>. PMID:17238192
11. Zhang Y, Fan M, Ren WD, et al. Prenatal diagnosis of fetal unilateral lung agenesis complicated with cardiac malposition. *BMC Pregnancy Childbirth.* 2013;13(1):79. <http://dx.doi.org/10.1186/1471-2393-13-79>. PMID:23530545

**Conflict of interest:** None

**Submitted on:** January 15, 2015

**Accepted on:** February 17, 2015

## Correspondence

Cesar Cilento Ponce MD, PhD

Av. Vicente de Carvalho, 65, 72 – Santos/SP – Brasil

CEP: 11045-501

Phone: +55 (13) 3284-0015 / Fax: +55 (13) 3226-0601

**E-mail:** cesarcponce@gmail.com