

Acquired hemophilia A in a patient with advanced prostate cancer

Daniel da Motta Girardi^a, Douglas Rafael Almeida Silva^b, Paula Ribeiro Villaça^b,
Ciro Eduardo Souza^a, Leonardo Gomes da Fonseca^a, Diogo Assed Bastos^a,
Paulo Marcelo Gehm Hoff^a

Girardi DM, Silva DRA, Villaça PR, et al. Acquired hemophilia A in a patient with advanced prostate cancer. *Autopsy Case Rep* [Internet]. 2015; 5(2):55-59. <http://dx.doi.org/10.4322/acr.2015.008>

ABSTRACT

Acquired hemophilia A (AHA) is a rare disorder that results from the presence of autoantibodies against the clotting factor VIII (FVIII) causing hemorrhagic disorders. This entity is mostly associated with autoimmune diseases, pregnancy, the postpartum period, drugs and malignancy. Among the solid cancers, prostate neoplasm is the most common cause of AHA. The management of AHA involves the control of active bleeding and the use of specific therapies to eliminate the inhibitor. The authors describe the case of an 87-year-old man with prostate cancer who developed a bleeding disorder 5 years after the cancer diagnosis. Treatment with prednisone did not reach a satisfactory clinical response, which was only achieved with the association of azathioprine. The patient became asymptomatic with no further bleeding episodes, but developed a fatal sepsis after 3 months of treatment with these immunosuppressive agents.

Keywords

Factor 8 deficiency, acquired; Prostatic Neoplasm; Hemorrhage.

INTRODUCTION

Acquired hemophilia A (AHA) is a rare and potentially life-threatening hemorrhagic disorder caused by the development of autoantibodies directed against the coagulation factor VIII (FVIII).¹

In approximately half of the cases, no underlying condition potentially related to the development of AHA can be identified; therefore, these cases are called idiopathic AHA.² In the remaining cases, the most commonly associated conditions are: autoimmune disorders, the postpartum period, and malignancy, present in approximately 10% of patients.³

Abnormal bleeding occurs in approximately 10% of patients with solid tumors, and in a higher proportion of patients with hematologic malignancies.⁴ The potential causes of new onset bleeding in patients with malignancy include pre-existing mild congenital hemophilia and other coagulation factor deficiencies, congenital von Willebrand disease, thrombocytopenia, neoplastic bone marrow invasion, chemo-radiation side-effects, decreased synthesis of coagulation factors due to liver dysfunction, disseminated intravascular coagulation, and acquired inhibitors against blood clotting factors.⁴ Moreover, since thromboembolic

^a Clinical Oncology Department - Instituto do Câncer do Estado de São Paulo, São Paulo/SP - Brazil.

^b Hospital das Clínicas - Faculdade de Medicina - Universidade de São Paulo, São Paulo/SP - Brazil.



events are very common in patients with advanced malignancies, a significant proportion of patients may develop bleeding events related to the use of prophylactic or therapeutic anti-thrombotic therapy.

The presence of cancer in AHA portends a worse outcome compared to patients who do not have an associated cancer.^{4,5} In the present report, we describe a rare event of malignancy-associated AHA.

CASE REPORT

An 87-year-old man was referred to the oncologic center because of an abnormal prostate-specific antigen (PSA) determination, which was tested during a routine evaluation. His physical examination was unremarkable except for an abnormal digital rectal examination, which demonstrated a firm prostate gland suspicious for prostate cancer. A prostatic biopsy was performed, which revealed a Gleason score 7 (3 + 4) adenocarcinoma. A radionuclide bone scan demonstrated an abnormal uptake in several ribs consistent with bone metastasis. His past medical history included hypertension and chronic kidney disease with an estimated creatinine clearance of 20 mL/min. His medications included amlodipine and hydrochlorothiazide and he did not take any anticoagulants or non-steroidal anti-inflammatory drugs. There was no personal or familial history of abnormal bleeding, and no altered blood clotting test was present at diagnosis.

Two months after the prostate cancer diagnosis, surgical castration was performed, which was followed by a significant decrease of the PSA determinations

with a nadir of 9 ng/dL. After 2 years, the patient developed castration-resistant disease and the PSA levels rose again. At that time, the patient started on a peripheral anti-androgen blockade with bicalutamide with a decline in transient PSA determinations followed by a rising PSA within 12 months. Subsequently, the patient received second-line therapy with prednisone 5 mg twice daily, leading to stabilization of the PSA levels at around 20.0 ng/dL.

Five years after the prostate cancer diagnosis, the patient developed gross hematuria, back pain, and spontaneous skin hematomas, and was admitted to the emergency department with severe anemia (hemoglobin determination of 4.8 g/dL (reference value [RV]: 13.0–18.0 g/dL) requiring red-blood-cell transfusion. Coagulation tests revealed a prothrombin time (PT) of 14.7 seconds and 83% of activity (RV: > 70%); active partial thromboplastin time (aPTT) of 97.7seconds (RV: 23–31 sec) and a fibrinogen level of 406 mg/dL (RV: 220–496 mg/dL). The active partial thromboplastin time was not corrected after mixing study neither lupus anticoagulants were identified. The patient's liver function tests were normal.

The clinical scenario of abnormal bleeding associated with these laboratory abnormalities led to the hypothesis of the presence of an inhibitor of the coagulation factor. The diagnosis of AHA was confirmed with the quantification of FVIII < 1% (RV: 50–150%) and the identification of the FVIII inhibitor that was quantified as 864 Bethesda Units (BU) (RV: < 0.6 BU). The PSA level was stable and a computerized tomography (CT) scan demonstrated no signs of new metastasis or evidence of cancer progression, but revealed an iliopsoas hematoma (Figure 1A and 1B).

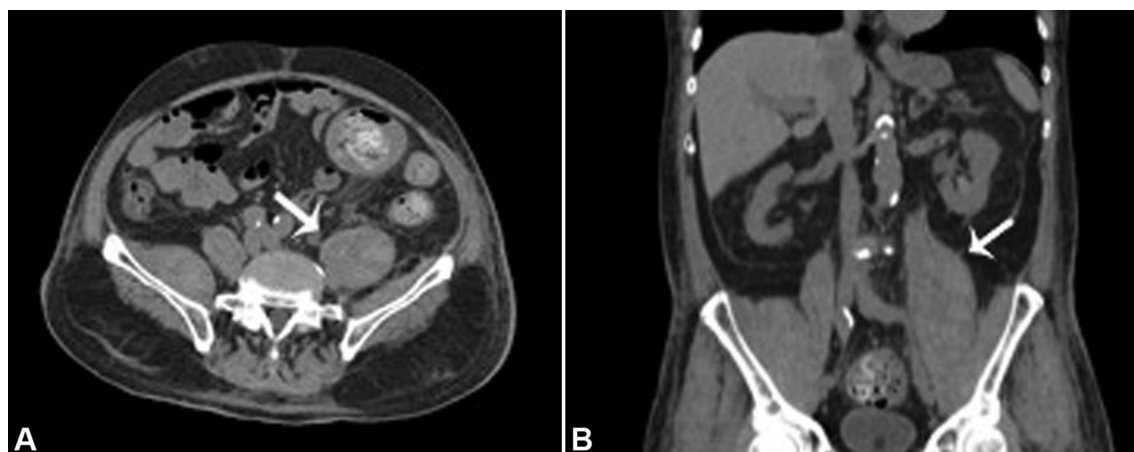


Figure 1. Abdominal CT. Axial (A) and coronal (B) planes showing volumetric enlargement of the left iliopsoas muscle (white arrows).

Once the diagnosis was confirmed, the treatment was initiated with prednisone 1 mg/kg per day without improvement during the first 48 hours. Therefore, a daily dose of 100 mg of azathioprine was added. On the following day, the hematuria ceased, the hemoglobin level remained stable, and no signs of new skin hematomas were observed. Homeostatic agents were not necessary at any time during the patient's hospitalization.

On the following days, a new CT study showed no further enlargement of the iliopsoas hematoma (Figure 2A and 2B) and the hematoma-associated back pain improved. The patient became asymptomatic and was discharged after 17 days of hospitalization.

Over the following 3 months after hospital discharge, the patient demonstrated a progressive fall of the inhibitor titles (lowest quantification of 7.6 UBTH) and an increase of the coagulation FVIII levels (28%). Furthermore, no other hemorrhage phenomenon was noted on follow-up. However, after 3 months, the patient was admitted to the Intensive Care Unit with the diagnosis of pneumonia, and died due to septic shock.

DISCUSSION

AHA is a rare disease caused by anti-FVIII autoantibodies. The incidence of AHA is 1.3–1.5 cases per million per year and up to 85% involve the elderly population.^{6,7}

The most common etiological factors associated with AHA are autoimmune disease, such as systemic lupus erythematosus, rheumatoid arthritis, or Sjögrens

syndrome, pregnancy, the postpartum period, drug-associated AHA, and malignancy.^{4,8} However, in approximately 50% of patients, no underlying disorder is detected.²

Underlying malignancy is present in about 10% of the cases of AHA.⁴ Among the solid cancers, prostate cancer is the most common cause of AHA followed by lung cancer.^{3,4} In the majority of cases, malignancy predates or is diagnosed concurrently with the bleeding disorder.⁴

The clinical manifestations of AHA are different from those observed in patients with congenital hemophilia. Whereas congenital hemophilia typically presents hemarthrosis in the younger male population, acquired hemophilia frequently presents with mucocutaneous or soft tissue bleeding in the elderly.⁴ Life-threatening hemorrhage occurs in about 9–22% of this population^{7,9} and the high mortality rate of 10–33% has been reported, which is due to spontaneous bleeding in most cases, or is related to associated conditions, such as cancer.⁶

The clinical presentation of cancer-associated AHA is similar to that observed in acquired AHA without any underlying malignancy, except for more genitourinary hemorrhage in the former, which is probably due to the predominance of prostate cancer among those cases.³ In 2001, Sallah and Wan³ reported that the most common sites of bleeding in patients with malignancy-associated AHA were soft tissue, hematuria, and skin.

No specific characteristic of the neoplasia, such as disseminated disease or histologic type, are associated with the development of AHA, and the reappearance

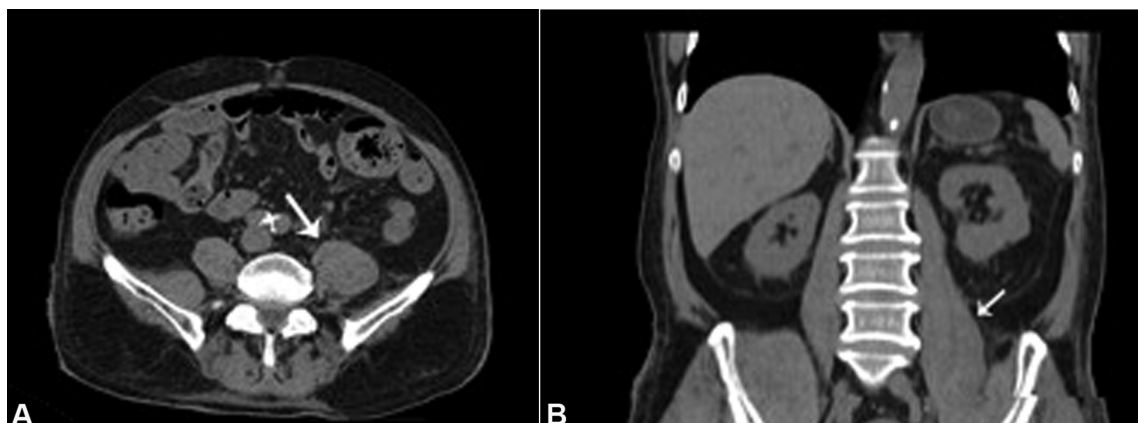


Figure 2. CT scan. Axial (A) and coronal (B) planes showing a mild decrease in the size of the left iliopsoas muscle hematoma (white arrows).

of the FVIII inhibitors is not associated with the neoplasm relapse.¹⁰

Due to the relative rarity of this condition, the diagnosis is often difficult and delayed.⁴ Initial testing usually reveals an isolated prolonged aPTT with a normal PT and platelet count, which are associated with a reduced level of FVIII.⁴ Importantly, the use of warfarin, heparin, and an abnormal liver function must be ruled out as alternative diagnoses.⁶ In AHA, the aPTT test after mixing study typically fails to normalize and can be misinterpreted as being related to a lupus inhibitor. Therefore, the International Guidelines for the diagnosis of AHA¹¹ recommend ruling out lupus anticoagulants by a specific test.⁶ In order to demonstrate the presence of the inhibitor, the Bethesda assay for the quantification of the inhibitor must be performed in these patients.^{6,9,11}

The management of AHA involves the control of active bleeding and specific therapies to eliminate the FVIII-inhibitor.⁶ The bleeding management can be done with homeostatic agents such as the recombinant FVIIa (rFVIIA), the activated prothrombin complex concentrate (aPCC), the 1-deamino-8-D-arginine vasopressin (DDAVP), and FVIII concentrates. In most cases, rFVIIa and aPCC have greater efficacy than human FVIII or DDAVP in achieving hemostasia, and must be the treatment of choice.^{4,11-13}

The international recommendations for the diagnosis and treatment of patients with AHA highlight the definition of treatment failure as: hemoglobin decrease despite red-blood-cell replacement, increasing dimensions of internal bleeding on imaging studies, evidence of continuous bleeding after 48 hours of appropriate treatment, bleeding on a new site, and increasing pain associated with hematoma despite treatment.¹¹

The deletion of the FVIII-inhibitor may be achieved with corticosteroids alone or corticosteroids associated with other immunosuppressant agents, such as cyclophosphamide or different combinations of azathioprine, rituximab, and cyclosporine A.^{6,11,14} Corticosteroids are the first-line therapy and may draw a complete remission in about 48% of patients, defined as undetectable FVIII-inhibitor levels and an FVIII higher than 70 IU/dL after the discontinuation of immunosuppressive therapy.¹⁴ The combination with cyclophosphamide not only increases the overall

response to 60–100%, but also may be associated with adverse effects, such as a higher incidence of infections.⁸ In 2007, Collins et al.⁷ did not find any difference in efficacy comparing corticosteroids alone with corticoids combined with cytotoxic agents, showing a complete remission rate of approximately 70%. This study also reported a rate of 33% of sepsis, which contributed to death in 11% of the cases.⁷ Others have demonstrated that the treatment of the underlying cancer with chemotherapy, surgery, or hormonal manipulation led to the disappearance of the inhibitor in 22% of patients. However, it is very difficult to speculate the exact role of oncologic therapy in this setting, since these results were not confirmed by other researchers.^{3,10}

REFERENCES

1. Franchini M, Gandini G, Di Paolantonio T, Mariani G. Acquired hemophilia A: a concise review. *Am J Hematol*. 2005;80(1):55-63. <http://dx.doi.org/10.1002/ajh.20390>. PMID:16138334.
2. Knoebl P, Marco P, Baudo F, et al. Demographic and clinical data in acquired hemophilia A: results from the European Acquired Haemophilia Registry (EACH2). *J Thromb Haemost*. 2012;10(4):622-31. <http://dx.doi.org/10.1111/j.1538-7836.2012.04654.x>. PMID:22321904.
3. Sallah S, Wan JY. Inhibitors against factor VIII in patients with cancer. Analysis of 41 patients. *Cancer*. 2001;91(6):1067-74. [http://dx.doi.org/10.1002/1097-0142\(20010315\)91:6<1067::AID-CNCR1101>3.0.CO;2-4](http://dx.doi.org/10.1002/1097-0142(20010315)91:6<1067::AID-CNCR1101>3.0.CO;2-4). PMID:11267950.
4. Reeves BN, Key NS. Acquired hemophilia in malignancy. *Thromb Res*. 2012;129(Suppl 1):S66-8. [http://dx.doi.org/10.1016/S0049-3848\(12\)70019-1](http://dx.doi.org/10.1016/S0049-3848(12)70019-1). PMID:22682137.
5. Bitting RL, Bent S, Li Y, Kohlwes J. The prognosis and treatment of acquired hemophilia: a systematic review and meta-analysis. *Blood Coagul Fibrinolysis*. 2009;20(7):517-23. <http://dx.doi.org/10.1097/MBC.0b013e32832ca388>. PMID:19644360.
6. Shetty S, Bhave M, Ghosh K. Acquired hemophilia a: diagnosis, aetiology, clinical spectrum and treatment options. *Autoimmun Rev*. 2011;10(6):311-6. <http://dx.doi.org/10.1016/j.autrev.2010.11.005>. PMID:21115138.
7. Collins PW, Hirsch S, Baglin TP, et al. Acquired hemophilia A in the United Kingdom: a 2-year national surveillance study by the United Kingdom Haemophilia Centre Doctors' Organisation. *Blood*. 2007;109(5):1870-7.

- <http://dx.doi.org/10.1182/blood-2006-06-029850>. PMID:17047148.
8. Delgado J, Jimenez-Yuste V, Hernandez-Navarro F, Villar A. Acquired haemophilia: review and meta-analysis focused on therapy and prognostic factors. *Br J Haematol*. 2003;121(1):21-35. <http://dx.doi.org/10.1046/j.1365-2141.2003.04162.x>. PMID:12670328.
 9. Franchini M, Targher G, Montagnana M, Lippi G. Laboratory, clinical and therapeutic aspects of acquired hemophilia A. *Clin Chim Acta*. 2008;395(1-2):14-8. <http://dx.doi.org/10.1016/j.cca.2008.05.003>. PMID:18505682.
 10. Hauser I, Lechner K. Solid tumors and factor VIII antibodies. *Thromb Haemost*. 1999;82(3):1005-7. PMID:10494753.
 11. Huth-Kühne A, Baudo F, Collins P, et al. International recommendations on the diagnosis and treatment of patients with acquired hemophilia A. *Haematologica*. 2009;94(4):566-75. <http://dx.doi.org/10.3324/haematol.2008.001743>. PMID:19336751.
 12. W Collins P, Chalmers E, Hart D, et al. Diagnosis and management of acquired coagulation inhibitors: a guideline from UKHCDO. *Br J Haematol*. 2013;162(6):758-73. <http://dx.doi.org/10.1111/bjh.12463>. PMID:23889317.
 13. Baudo F, Collins P, Huth-Kühne A, et al. Management of bleeding in acquired hemophilia A: results from the European Acquired Haemophilia (EACH2) Registry. *Blood*. 2012;120(1):39-46. <http://dx.doi.org/10.1182/blood-2012-02-408930>. PMID:22618709.
 14. Collins P, Baudo F, Knoebl P, et al. Immunosuppression for acquired hemophilia A: results from the European Acquired Haemophilia Registry (EACH2). *Blood*. 2012;120(1):47-55. <http://dx.doi.org/10.1182/blood-2012-02-409185>. PMID:22517903.

Conflict of interest: None

Submitted on: March 20, 2015

Accepted on: May 15, 2015

Correspondence

Daniel da Motta Girardi
 Instituto do Câncer do Estado de São Paulo
 Av. Dr. Arnaldo, 251 – Sumaré/SP, Brazil
 CEP: 01246-000
 Phone: +55 (11) 3893-2000 / +55 (11) 98273-2100
E-mail: danielmgirardi@gmail.com