

Bilateral mandibular osteomyelitis mimicking periapical cysts in a patient with sickle cell anemia

Juliane Piráguine Araújo^a, Ana Maria Hoyos Cadavid^a, Celso Augusto Lemos^a,
Marilia Trierveiler^b, Fabio Abreu Alves^{a,c}

Araújo JP, Cadavid AMH, Lemos CA, Trierveiler M, Alves FA. Bilateral mandibular osteomyelitis mimicking periapical cysts in a patient with sickle cell anemia. *Autopsy Case Rep* [Internet]. 2015;5(3):55-60. <http://dx.doi.org/10.4322/acr.2015.013>

ABSTRACT

Sickle cell anemia (SCA) is a hemoglobin disorder that occurs more commonly among Afro-descendants. The authors report the case of a 28-year-old Afro-descendent male patient with the diagnosis of homozygotic sickle cell disease (SCD) referred for evaluation of mandibular lesions. The patient's main complaints included pain and bilateral teeth mobility. An intraoral examination revealed gingiva recession affecting the lower molars with extensive root exposure. A panoramic x-ray showed two radiolucent symmetrical periapical lesions evolving both the first and the second lower molars, bilaterally. The diagnostic hypotheses comprised odontogenic infection, among others. Besides antimicrobial therapy, the two molars of both sides were extracted and bone was collected for histopathological and microbiological analyses. Osteomyelitis was diagnosed, and *Streptococcus viridans* was recovered from the culture media. Mandibular osteomyelitis should be considered as a diagnosis in patients with SCD. The present case offers an alert to clinicians about the importance of knowing jaw lesions related to SCA.

Keywords

Osteomyelitis; Anemia, Sickle Cell; Mandible.

INTRODUCTION

Sickle cell anemia (SCA) is a common genetic condition characterized by the presence of abnormal hemoglobin, designated hemoglobin S (HbS), and is particularly common among people whose ancestors come from sub-Saharan Africa, India, Saudi Arabia, and Mediterranean countries. The red blood cells become sickle-shaped, blocking capillaries. Consequently, a low level of oxygen reaches the tissues and the patients will present recurrent painful crises, bone or joint necrosis,

and renal failure. Blood transfusion and iron-chelation therapy may be necessary in severe cases.¹

Osteomyelitis, due to altered blood supply associated with sickle cell disease (SCD), is more commonly observed in long bones. In the jaw bones, the posterior region of the mandible is the area most frequently affected, and oral microorganisms may reach this area via periodontal ligaments or by hematogenous spread.²⁻⁴ In addition, vaso-occlusive

^a Stomatology Department - School of Dentistry - Universidade de São Paulo, São Paulo/SP – Brazil.

^b Oral Pathology Department - School of Dentistry - Universidade de São Paulo, São Paulo/SP – Brazil.

^c Stomatology Department - AC Camargo Cancer Center, São Paulo/SP – Brazil.



radiopaque lesions can be observed in the mandible and can represent mandibular infarcts whose onset coincides with severe facial pain in sickling crises. As the initial radiographic appearance of infarction may be identical to that seen in osteomyelitis, clinical and laboratory features can help to distinguish infarction and osteomyelitis, which involve different therapeutic approaches.⁵⁻⁷

The aim of this report is to describe a case of bilateral mandibular osteomyelitis related to SCD, which could be misdiagnosed as periapical cyst.

CASE REPORT

A 28-year-old Afro-descendent male was referred to our institution for evaluation of painful mandibular lesions. His medical history included homozygotic SCA diagnosis and some previous hospitalizations due to chest and femoral pain. (His most recent hospitalization occurred 1-month prior, when antibiotics and a blood transfusion were prescribed.) Intraoral examination showed extensive root exposure affecting the lingual side of the right and the left lower molars, localized gingival purulent drainage, mobility, and caries in those

teeth (Figure 1A-1D). The panoramic radiography showed two radiolucent symmetrical periapical lesions evolving both the first and the second lower molars, bilaterally (Figure 2).

The main differential diagnoses were odontogenic infection, periapical cyst and keratocystic odontogenic tumor related to nevoid basal cell carcinoma syndrome (KOCT-NBCCS). Some hematological exams were requested, and the results were: 3.09 million/mm³ red cells, 8.9 g/dL of hemoglobin, red cell distribution width 22%, anisocytosis (+++), 14,400 /mm³ leukocytes, 320,000 /mm³ platelets, the presence of sickle erythrocytes, 1:30 min bleeding time, and prothrombin time was normal. The clinical management consisted of an antimicrobial prescription followed by extraction of the first and the second lower molars (on both sides of the mandible). During the procedure, a sequestrum of alveolar bone was removed. In addition, tissue fragments for histopathology and microorganism culture were sampled. The histopathological findings consisted of granulation tissue with lymphoplasmacytic inflammatory infiltrate and areas with bacterial colonies and microabscesses. A large fragment of necrotic bone was also observed (Figure 3A and 3B).

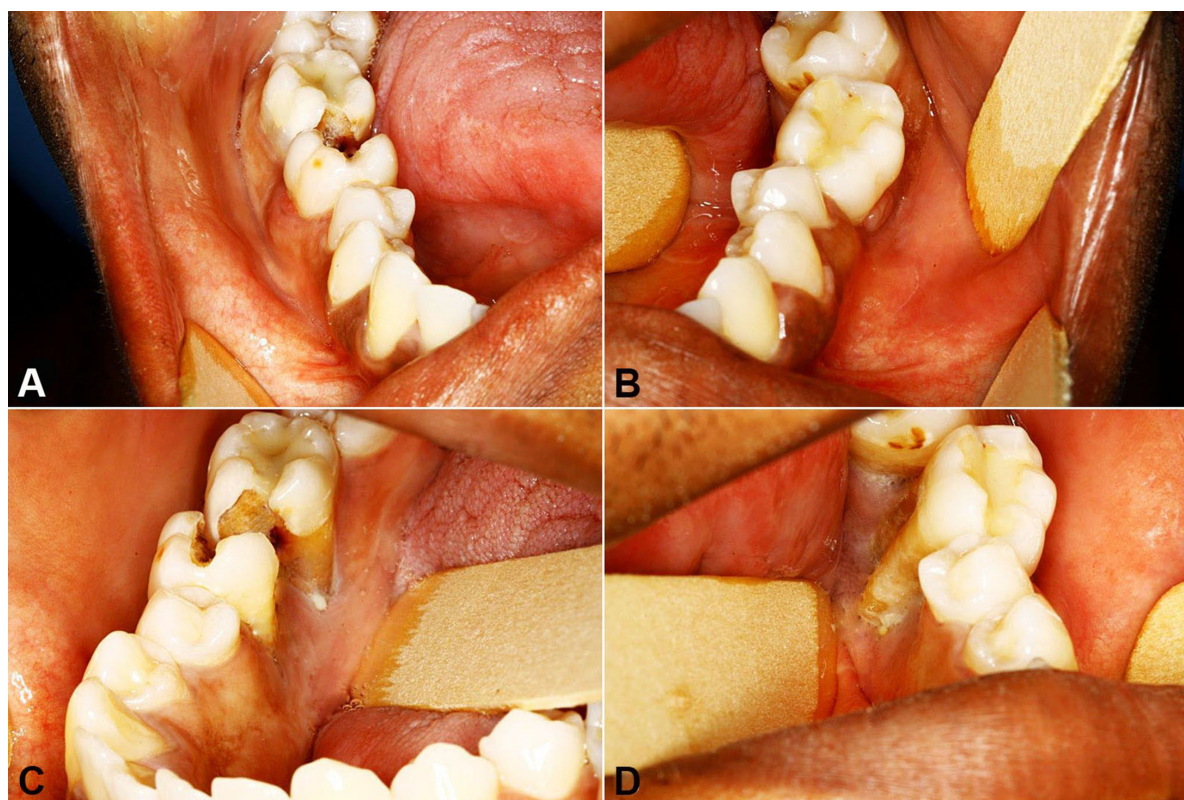


Figure 1. **A** and **C** – Right molars presenting caries and lingual root exposure; **B** and **D** – Left molars with extensive lingual root exposure.

The culture of the lesion showed the growth of *Streptococcus viridans*, which was sensitive to penicillin, clindamycin, erythromycin, and vancomycin. Anaerobic bacteria were not recovered in the culture media. The patient was followed-up for 3 months and has been asymptomatic ever since (Figure 4A-4C).

DISCUSSION

SCA is characterized by the synthesis of an abnormal hemoglobin molecule (HbS), which is a result of point mutation in the hemoglobin gene. There is the substitution of the valine for glutamic acid as the sixth amino acid of the beta chain, which results in abnormal reactions between molecules of HbS when oxygen tension is lowered. The polymerization of deoxygenated HbS is the primary event in the molecular pathogenesis of SCD, resulting in a distortion of the shape of the erythrocyte and a marked decrease

in its ability to deform.⁸ Thus, the red blood cell lifespan is decreased from 120 days to 10-12 days, resulting in hemolytic anemia.^{2,9} The increased susceptibility of SCD patients to infections, including osteomyelitis, has long been recognized by several mechanisms, including hyposplenism and the presence of infarcted or necrotic bone.³ A sickle cell crisis may be spontaneously triggered, but patients may describe specific events preceding the pain crisis, such as cold temperature, emotional stress, anxiety, or other painful states, such as tooth pain.²

Aseptic necrosis has been more frequently observed in long bones than in the mandible. Interestingly, *Salmonella* sp is more related to the former, and *Streptococcus* sp and *Staphylococcus aureus* to the latter.^{3,8} Olaitan et al.¹⁰ evaluated 16 patients with mandibular osteomyelitis associated with SCA: 13 were men (81%) and the majority of them were in the third decade of life (mean age = 23 years). All lesions were located in the mandible (angle and ascending ramus). Mixed flora and *S. aureus* infection was the predominant agents and no *Salmonella* sp was isolated in that study.

Increased radiolucency of bone is more commonly observed in the area between the apices of the lower teeth. In addition, suppurative osteomyelitis usually presents as indistinct radiolucency and painful osseous resorption.⁸ In the present case, two symmetrical and well-defined radiolucent lesions were observed in the body of the mandible (the lesions involved the roots of the first and second molars, bilaterally). Such

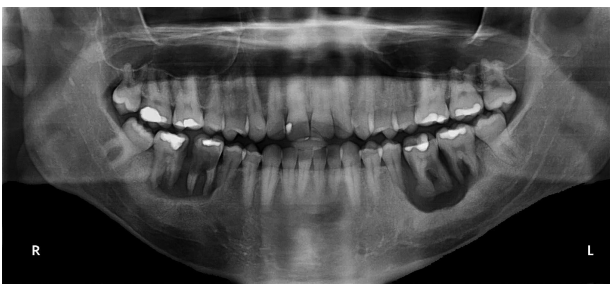

Figure 2. Panoramic x-ray showing two symmetrical radiolucent lesions involving the roots of the lower molars.

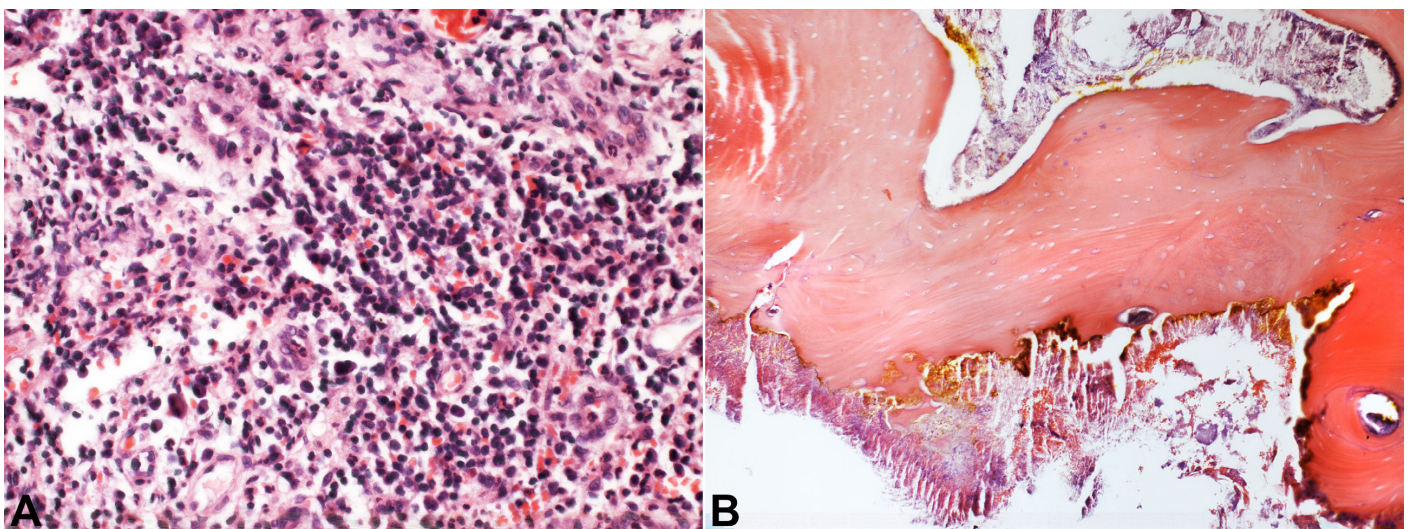


Figure 3. A – Intense lymphoplasmacytic inflammatory infiltrate (HE, 400X); **B** – Necrotic bone presenting bacterial colonies (HE, 100X).

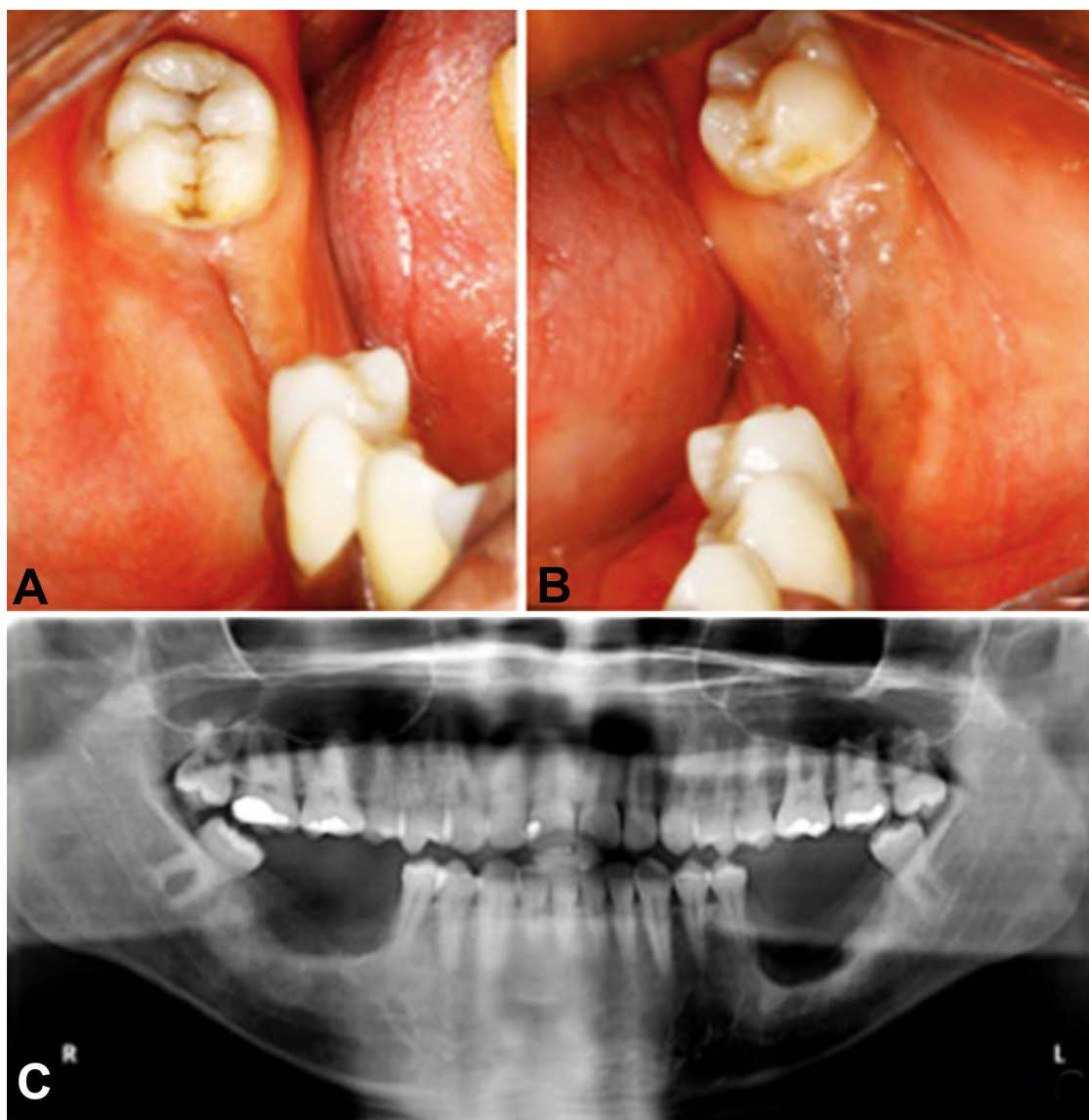


Figure 4. A-C – Clinical and radiographic control 3 months after the surgeries.

lesions had radiographic features similar to that of periapical cysts. Extensive caries and restorations also contributed to cyst diagnosis. Furthermore, keratocystic odontogenic tumors related to nevoid basal cell carcinoma syndrome can be a differential diagnosis mainly because the lesions were synchronic. However, a thin sclerotic halo, which is commonly observed in cystic lesions, was not present in our case. Another interesting radiographic feature is a small radiopaque area around the apices of the left first lower molar suggesting bone sequestrum, which was confirmed during surgery.

Although we did not perform the dental pulp sensibility test, the extensive caries of the right first and second molars and the advanced periodontal diseases in the left molars likely caused the pulp

necrosis of those teeth (Figure 1A-1D). In our opinion, this information was not essential in the present case, since these patients usually present asymptomatic pulpal necrosis and increased incidence of dental caries, mandibular osteomyelitis, mandibular nerve anesthesia, and the aforementioned radiographic findings.^{3,4} In addition, Guzeldemir et al.¹¹ reported that plaque and gingival indices were significantly higher in patients with SCD than in healthy individuals.

The treatment of odontogenic infections usually includes the removal of the causative tooth, followed by drainage and antibiotic therapy.¹² Antibiotic prophylaxis for oral surgical procedures is recommended, not only because of the patient's increased risk for infection, but also because infection can potentially induce hemolytic crisis. Penicillin V, amoxicillin, and clindamycin are

acceptable preoperative oral antibiotics and should be administered approximately 1 hour before the procedure.² Treatment of SCA osteomyelitis in most of the reported mandibular cases included sequestrectomy and debridement of the infected areas, along with the appropriate antibiotic prescription. However, antibiotics alone remain the mainstay of bone infection treatment in SCA. Surgery should be limited to diagnosis and therapeutic drainage of an obvious periosteal abscess or a sequestrectomy.⁶ The treatment of our case included exodontia of the lower first and second molars, administration of amoxicillin 500 mg three times daily for 2 weeks, curettage of the lesion, and wound closure. The patient had a good postoperative period without pain or bleeding. The wound showed a mild healing delay on the left side compared with the right side.

CONCLUSION

This case illustrates that patients with SCA can present oral abnormalities with challenging diagnosis and management. Furthermore, the osteomyelitis is an important differential diagnosis of radiolucent jaw lesions.

ACKNOWLEDGEMENTS

The authors are grateful to the Brazilian Federal Agency for the Support and Evaluation of Graduate Education—CAPES—and the National Council for Scientific and Technological Development—CNPq—for their financial support.

REFERENCES

1. World Health Organization (WHO). Sickle cell anaemia, in Report by the Secretariat in Provisional Agenda Item 11.4. A59/9. Geneva: WHO; 2006.
2. Stanley AC, Christian JM. Sickle cell disease and perioperative considerations: review and retrospective report. *J Oral Maxillofac Surg.* 2013;71(6):1027-33. <http://dx.doi.org/10.1016/j.joms.2012.12.004>. PMID:23434171.
3. Almeida A, Roberts I. Bone involvement in sickle cell disease. *Br J Haematol.* 2005;129(4):482-90. <http://dx.doi.org/10.1111/j.1365-2141.2005.05476.x>. PMID:15877730.
4. Kelleher M, Bishop K, Briggs P. Oral complications associated with sickle cell anemia: a review and case report. *Oral Surg Oral Med Oral Pathol Oral Radiol Endod.* 1996;82(2):225-8. [http://dx.doi.org/10.1016/S1079-2104\(96\)80261-7](http://dx.doi.org/10.1016/S1079-2104(96)80261-7). PMID:8863314.
5. Sanger RG, Greer RO Jr, Averbach RE. Differential diagnosis of some simple osseous lesions associated with sickle-cell anemia. *Oral Surg Oral Med Oral Pathol.* 1977;43(4):538-45. [http://dx.doi.org/10.1016/0030-4220\(77\)90106-2](http://dx.doi.org/10.1016/0030-4220(77)90106-2). PMID:265481.
6. Lawrenz DR. Sickle cell disease: a review and update of current therapy. *J Oral Maxillofac Surg.* 1999;57(2):171-8. [http://dx.doi.org/10.1016/S0278-2391\(99\)90234-3](http://dx.doi.org/10.1016/S0278-2391(99)90234-3).
7. Kavadia-Tsatata S, Kolokytha O, Kaklamanos EG, Antoniadis K, Chasapopoulou E. Mandibular lesions of vasoocclusive origin in sickle cell hemoglobinopathy. *Odontology.* 2004;92(1):68-72. <http://dx.doi.org/10.1007/s10266-004-0036-3>. PMID:15490308.
8. Sansevere JJ, Milles M. Management of the oral and maxillofacial surgery patient with sickle cell disease and related hemoglobinopathies. *J Oral Maxillofac Surg.* 1993;51(8):912-6. [http://dx.doi.org/10.1016/S0278-2391\(10\)80114-4](http://dx.doi.org/10.1016/S0278-2391(10)80114-4). PMID:8336229.
9. Shroyer JV 3rd, Lew D, Abreo F, Unhold GP. Osteomyelitis of the mandible as a result of sickle cell disease: report and literature review. *Oral Surg Oral Med Oral Pathol.* 1991;72(1):25-8. [http://dx.doi.org/10.1016/0030-4220\(91\)90184-E](http://dx.doi.org/10.1016/0030-4220(91)90184-E). PMID:1891241.
10. Olaitan AA, Amuda JT, Adekeye EO. Osteomyelitis of the mandible in sickle cell disease. *Br J Oral Maxillofac Surg.* 1997;35(3):190-2. [http://dx.doi.org/10.1016/S0266-4356\(97\)90562-3](http://dx.doi.org/10.1016/S0266-4356(97)90562-3). PMID:9212297.
11. Guzeldemir E, Toygar HU, Boga C, Cilasun U. Dental and periodontal health status of subjects with sickle cell disease. *J Dent Sci.* 2011;6(4):227-34. <http://dx.doi.org/10.1016/j.jds.2011.09.008>.
12. Farmahan S, Tuopar D, Ameerally PJ. The clinical relevance of microbiology specimens in head and neck space infections of odontogenic origin. *Br J Oral Maxillofac Surg.* 2014;52(7):629-31. <http://dx.doi.org/10.1016/j.bjoms.2014.02.027>. PMID:24906248.

Conflict of interest: None

Submitted on: March 7, 2015

Accepted on: June 20, 2015

Correspondence

Fabio Abreu Alves

Rua Prof Antonio Prudente, 211 – Liberdade

CEP: 01509-900 – São Paulo/SP – Brazil

Phone: +55 (11) 2189-5129

E-mail: falves@accamargo.org.br